

CASE REPORT

Open Access



Echocardiography-guided subxiphoidal transapical TAVR in a challenging anatomy: a case report

Andres Beiras-Fernandez¹, Angela Kornberger^{1*} , Martin Geyer², Alexander Tamm² and Ralph Stephan von Bardeleben²

Abstract

Background: Transcatheter aortic valve replacement (TAVR) via an antegrade transapical access (TA-TAVR) is largely reserved to cases not amenable to transfemoral TAVR. Challenges resulting from unusual thoracic anatomies may require special considerations in terms of the surgical access.

Case presentation: We present a case of TA-TAVR through a subxiphoidal approach in a patient who had undergone extensive thoracic surgery 8 years previously.

Conclusion: Our case demonstrates that unusual anatomic features should not discourage from TA-TAVR but may require unusual approaches designed on a case-to-case basis following careful interdisciplinary preparation and planning including adequate pre-operative diagnostics and imaging.

Keywords: Transcatheter aortic valve replacement, Modified transapical access, Subxiphoidal approach, Case report

Background

Transcatheter aortic valve replacement (TAVR) has become the standard method for the treatment of aortic valve stenosis in intermediate and high risk patients and is mostly performed via a retrograde transfemoral route (TF-TAVR). The antegrade transapical access (TA-TAVR) is largely reserved – with some degree of local variability and preference - to cases not amenable to TF-TAVR because the iliofemoral arteries are too narrow, tortuous, diseased or calcified [1–3]. In cases scheduled for TA-TAVR, challenges in terms of the access may result from extreme obesity, unusual anatomic characteristics or changes caused by prior thoracic surgery. We present a modified subxiphoidal access that may be used in cases where the heart has shifted rightwards such as

in our patient, whose anatomy was very distinct following previous thoracic surgery.

Case presentation

We present the case of a 76 year old female who was referred for TAVR with an extensive medical history including right upper and middle lobectomy for bronchial carcinoma 8 years previously, long-standing GOLD IV COPD with steroid treatment and recurrent exacerbations, coronary three vessel disease with a history of several myocardial infarctions and repeated PCI, diabetes mellitus, carotid artery disease, and peripheral artery disease that had been treated by stenting and bypass grafting. Her Euroscore II was 3.92 / log Euroscore I 26.45%.

TF-TAVR was not feasible due to multiple stenoses of the iliofemoral vessels with presence of several bypasses and a stent protruding from the right common iliac artery into the iliac bifurcation. The subclavian, direct

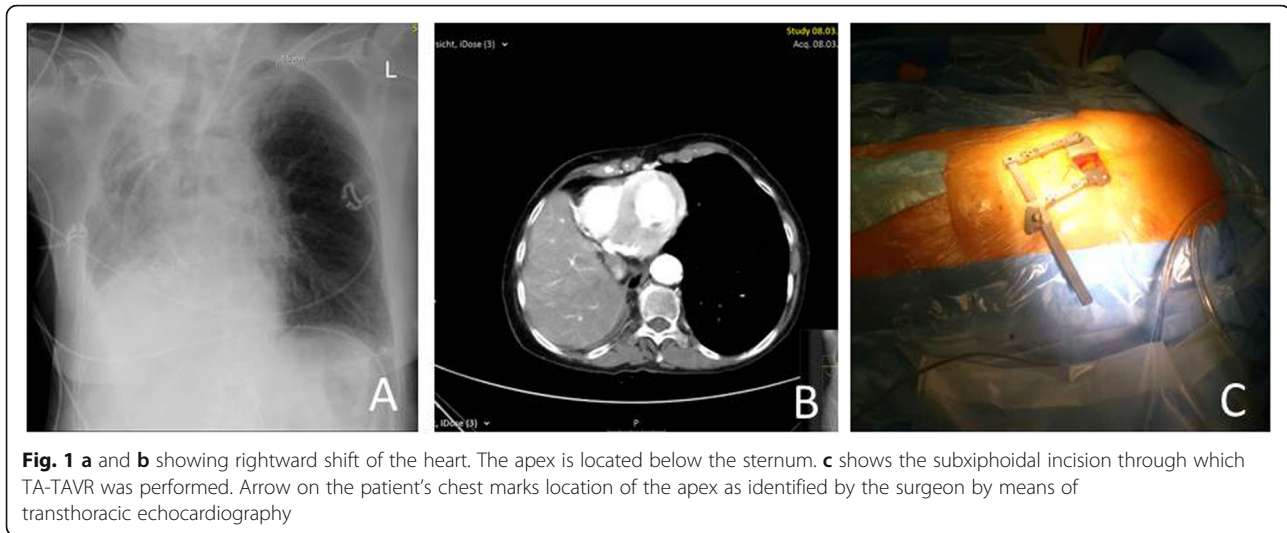
* Correspondence: angela.kornberger@unimedizin-mainz.de

¹Department of Cardiothoracic and Vascular Surgery, University Medical Center Mainz (Johannes Gutenberg-University Mainz), Langenbeckstr. 1, 55131 Mainz, Germany

Full list of author information is available at the end of the article



© The Author(s). 2020 **Open Access** This article is licensed under a Creative Commons Attribution 4.0 International License, which permits use, sharing, adaptation, distribution and reproduction in any medium or format, as long as you give appropriate credit to the original author(s) and the source, provide a link to the Creative Commons licence, and indicate if changes were made. The images or other third party material in this article are included in the article's Creative Commons licence, unless indicated otherwise in a credit line to the material. If material is not included in the article's Creative Commons licence and your intended use is not permitted by statutory regulation or exceeds the permitted use, you will need to obtain permission directly from the copyright holder. To view a copy of this licence, visit <http://creativecommons.org/licenses/by/4.0/>. The Creative Commons Public Domain Dedication waiver (<http://creativecommons.org/publicdomain/zero/1.0/>) applies to the data made available in this article, unless otherwise stated in a credit line to the data.



aortic and trans-caval approaches were considered but deemed not feasible due to a stenosis of the left subclavian artery, a heavily calcified, abnormally located ascending aorta, and a heavily calcified abdominal aorta with an acute-angled kink and chronically dissected aneurysm, respectively. CT additionally showed that the mediastinal structures were dislocated rightwards to such a degree that the apex could not be reached through the typical anterolateral incision used for TA-TAVR (Fig. 1a, b). The apex was therefore accessed through an untypical subxiphoidal incision without affecting the sternum or the ribs (Fig. 1c). Pre-incision transthoracic echocardiography allowed us to locate the apex directly below the xyphoid, allowing the incision to be kept extremely small. TA-TAVR using a 23 mm Sapiens 3 (Edwards Lifesciences, Irvine, USA) valve was performed in standard fashion without complications. After the procedure, the patient took a prolonged course due to pneumonia requiring re-intubation and was finally discharged after an ICU stay and total postoperative hospital stay of 6 and 17 days, respectively. Follow-up after 4 months showed her in a good functional condition with a mean aortic valve gradient of 7 mmHg and no relevant aortic regurgitation.

Discussion and conclusions

In conclusion, unusual anatomic features should not discourage from TA-TAVR but may in certain cases be compensated by unusual approaches designed on a case-to-case basis. Pre-incision transthoracic echocardiography allows precise identification of the incision site so that the dimensions of the incision can be kept to a minimum. Alternatives to TA access these cases, including TAVR through carotid, subclavian or

trans-caval access should be considered depending on patient anatomy and the type of bioprosthesis to be implanted. Treatment at a high-volume center and extensive implanter experience in TA-TAVR and other transapical procedures are mandatory for success.

Abbreviations

TA: Transapical; TF: Transfemoral; TAVR: Transcatheter aortic valve replacement

Acknowledgments

Not applicable.

Authors' contributions

A.B.F. supervised the project, contributed to the drafting, reviewed the manuscript and approved the final version. A.K. contributed to the collection of medical data and drafting of the manuscript and approved the final version. M.G. contributed to the drafting of the manuscript and preparation of images and approved the final version. A.T. contributed to the drafting of the manuscript and preparation of images and approved the final version. R.S.v.B. designed the project outline, critically reviewed the manuscript and approved the final version.

Funding

The authors have not received funding for the preparation of the present manuscript.

Availability of data and materials

The datasets used and/or analyzed during the current study are available from the corresponding author on reasonable request.

Ethics approval and consent to participate

The patient provided consent for the publication of her case including any individual details, images or videos.

Consent for publication

The patient provided consent for the publication of her case including any individual details, images or videos.

Competing interests

The authors declare that they have no competing interests.

Author details

¹Department of Cardiothoracic and Vascular Surgery, University Medical Center Mainz (Johannes Gutenberg-University Mainz), Langenbeckstr. 1, 55131 Mainz, Germany. ²Center for Cardiology, Cardiology I, University Medical Center Mainz (Johannes Gutenberg-University Mainz), Mainz, Germany.

Received: 6 January 2020 Accepted: 2 June 2020

Published online: 09 June 2020

References

1. Blackstone EH, Suri RM, Rajeswaran J, Babaliaros V, Douglas PS, Fearon WF, et al. Propensity-matched comparisons of clinical outcomes after Transapical or Transfemoral TAVR: a PARTNER-I trial substudy. *Circulation*. 2015;131(22):1989–2000.
2. Kumar N, Khera R, Fonarow GC, Bhatt DL. Comparison of outcomes of Transfemoral versus Transapical approach for Transcatheter aortic valve implantation. *Am J Cardiol*. 2018;122(9):1520–6.
3. Takahide A, Romano M, Lefèvre T, Hovasse T, Farge A, Le Houerou D, et al. Direct comparison of feasibility and safety of Transfemoral versus Transaortic versus Transapical Transcatheter aortic valve replacement. *JACC Cardiovasc Interv*. 2016;9(22):2320–5.

Publisher's Note

Springer Nature remains neutral with regard to jurisdictional claims in published maps and institutional affiliations.

Ready to submit your research? Choose BMC and benefit from:

- fast, convenient online submission
- thorough peer review by experienced researchers in your field
- rapid publication on acceptance
- support for research data, including large and complex data types
- gold Open Access which fosters wider collaboration and increased citations
- maximum visibility for your research: over 100M website views per year

At BMC, research is always in progress.

Learn more biomedcentral.com/submissions

