

CASE REPORT

Open Access



A practical technique for subacute hemorrhagic pericarditis, a case report

Long Zhao, Ruofeng Hong, Jianbin Fei and Wenyu Yang*

Abstract

Background: We used pericardioscope operation for a patient who suffered from subacute hemorrhagic pericarditis which usually have to had a sternotomy.

Case presentation: A pericardioscope was used in the operation rather than sternotomy on a 66-year-old male who was diagnosed with subacute hemorrhagic pericarditis after PCI(Percutaneous Coronary Intervention). He was discharged 7 days after the operation with an uneventfull postoperative course.

Conclusions: We believe that this technique is a safe procedure without any major complications.

Keywords: Subacute hemorrhagic pericarditis, Viscous effusion, Endoscopic surgery, Case report

Background

Most of the pericardial effusion was drained by pericardiocentesis, but for those with hemorrhagic effusion, especially with blood clot or subacute hemorrhagic pericarditis, effectively drainage was hard to achieve, sternotomy was unavoidable then. To minimize the trauma, we inserted a thoracoscope into the pericardiac space to remove the blood clot for a patient and got a wonderful outcome.

Case presentation

A 66-year-old male was admitted to Ningbo Hwa Mei Hospital in July 21, 2020 because of repeated pericardial effusion. He underwent PCI due to Coronary Atherosclerotic Heart Disease in July 3, 2020. He complained pectoralgia for 1 week before hospitalization. Echocardiography showed massive pericardial effusion. Percutaneous pericardiocentesis was performed and about 2400 ml hemorrhagic effusion was drained in the next 6 days. Chest Computed Tomography(CT) and echocardiography on August 7th showed massive pericardial hemorrhage

with blood clot. Operation was advised. But the patient claimed explicitly that he would rather die than have a sternotomy because of his concern about the incision infection due to the diabetes and obesity and the disunion of the sternum due to the osteoporosis which caused by renal failure he had suffered for several years. So we performed a minimally invasive surgery.

Method

The patient was placed on his right side and the surgical approach was through the left pleural space. A pneumothorax was created with partial pulmonary collapse to allow an adequate view of the pericardial surface. A 3-cm incision was made at the left 5th intercostal space, in the midclavicular line. The telescope was passed through the incision. We inspected the pleural space and pericardial surface, identified the left phrenic nerve to avoid damage. A pericardiotomy was performed, some of the bloody effusion was drained, but the blood clot has formed adhesion and was difficult to remove, a partial pericardiectomy of 4*4 cm was done. The pericardial space was then inspected through the telescope.

The pericardium was caught by double joint oval forceps and lift up. After the blood clot under the incision was excavated by another double joint oval forceps, the

* Correspondence: mgyang21100@sina.com

Cardiovascular Surgery Department, Hwa Mei Hospital, University of Chinese Academy of Sciences; Ningbo Institute of Life and Health Industry, University of Chinese Academy of Sciences, Room 201, Oriental Venice, Haishu District, Ningbo City, Zhejiang Province, China



© The Author(s). 2021 **Open Access** This article is licensed under a Creative Commons Attribution 4.0 International License, which permits use, sharing, adaptation, distribution and reproduction in any medium or format, as long as you give appropriate credit to the original author(s) and the source, provide a link to the Creative Commons licence, and indicate if changes were made. The images or other third party material in this article are included in the article's Creative Commons licence, unless indicated otherwise in a credit line to the material. If material is not included in the article's Creative Commons licence and your intended use is not permitted by statutory regulation or exceeds the permitted use, you will need to obtain permission directly from the copyright holder. To view a copy of this licence, visit <http://creativecommons.org/licenses/by/4.0/>. The Creative Commons Public Domain Dedication waiver (<http://creativecommons.org/publicdomain/zero/1.0/>) applies to the data made available in this article, unless otherwise stated in a credit line to the data.

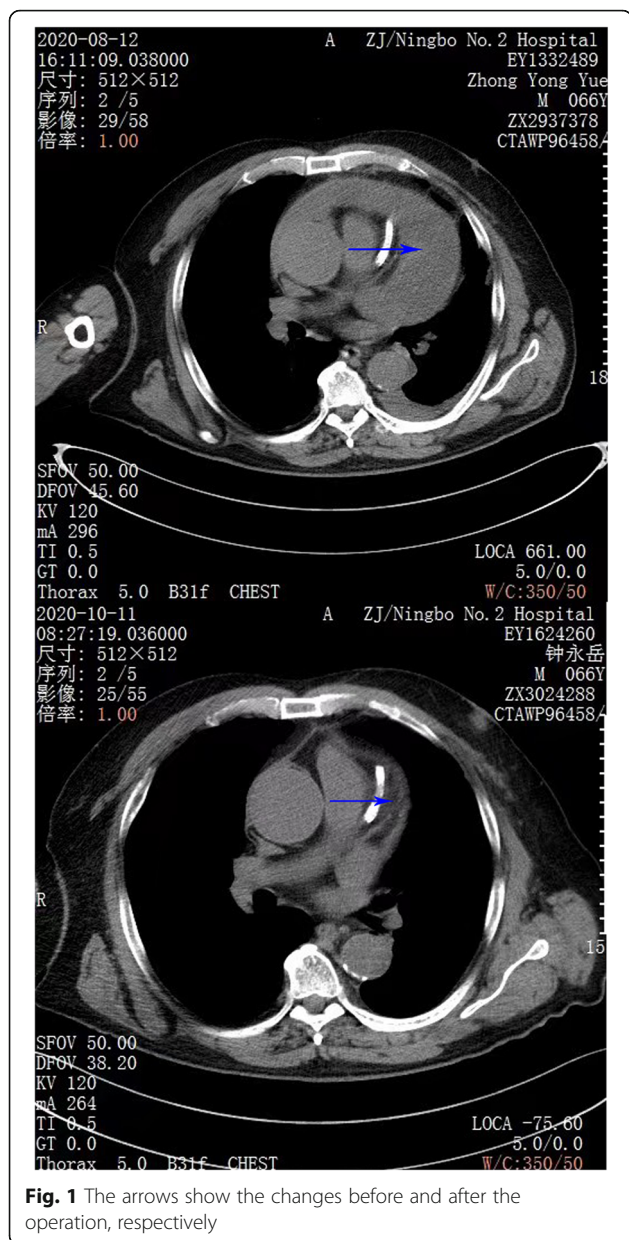


Fig. 1 The arrows show the changes before and after the operation, respectively

thoracoscope was inserted into the pericardial cavity through the pericardial incision. Take the advantage of the 30° slope of the thoracoscope, we can observe different directions by turn the scope without move the shaft. To obtain a better view, we used a curved double joint forceps to enlarge the pericardial cavity by using the turning of the forceps to lift the pericardium. After cleaning the left part of the pericardial cavity, we turn the scope to the anterior and right lateral cavity to clean the blood clot until the level of superior vena cava. It is hard to avoid squeezing the heart during the procedure, so the ECG(Electrocardiogram) and blood pressure must be payed attention to during the operation. A drainage tube was insert into the pericardial cavity and the incision was sutured in layers. Another drainage tube was placed in the pleural space under direct vision and connected to underwater seal. The postoperative course was uneventfull. He was discharged 7 days after the operation. A chest CT on October 11th showed there was almost no pericardial effusion left (Fig. 1, Fig. 2).

Discussion

Pericardial effusion limits cardiac expansion and increases atrial, ventricular, and pericardial pressures. The result is a reduction in cardiac output, and vasoconstriction to maintain the blood pressure [1–3]. A common way to drain the effusion is pericardiocentesis subxiphoidly. However, it is often unable to provide sustainable results with a high rate of recurrence and low rate of diagnosis [4]. The best method to treat the pericardial effusions remains a controversial subject. Nevertheless, with the advancement of minimally invasive procedures in cardiovascular surgery, it has become the first choice and increasing reports have shown the efficacy, safety and reproducibility of the thoracoscopic procedure [5–8]. But for those with viscous effusion, like subacute hemorrhagic pericarditis, the efficiency of pericardial fenestration through a video-thoracoscopic or subxiphoid approach [9] is limited. By inserting the thoracoscope into the pericardial cavity, lifting the parietal pericardium with a double joint forceps can create a promising space to observe and scrape the viscous effusion. Benefit from the 30 degree slope of the lenses of the thoracoscope, a larger vision can be obtained by

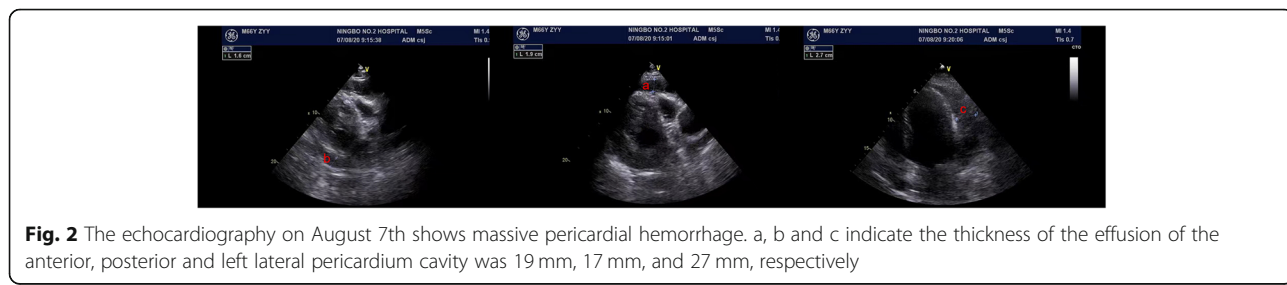


Fig. 2 The echocardiography on August 7th shows massive pericardial hemorrhage. a, b and c indicate the thickness of the effusion of the anterior, posterior and left lateral pericardium cavity was 19 mm, 17 mm, and 27 mm, respectively

rotation and propulsion of the shaft. During the procedure, an extra attention must be paid to avoid squeezing the free wall of ventricles roughly so as not to cause ventricular rupture or hemodynamic instability. Other than transient arrhythmias, the procedure is not associated with major complications.

Conclusion

Pericardioscope is an effective and practical technique for subacute hemorrhagic pericarditis which should be applied in more patients.

Abbreviations

PCI: Percutaneous Coronary Intervention; CT: Computed Tomography; ECG: Electrocardiogram

Supplementary Information

The online version contains supplementary material available at <https://doi.org/10.1186/s13019-021-01499-7>.

Additional file 1.

Acknowledgements

Not applicable.

Authors' contributions

Wenyu Yang designed and conducted the operation. Ruofeng Hong and Jianbin Fei collected the clinical data. Long Zhao wrote the manuscript. All authors read and approved the final manuscript.

Funding

Not applicable.

Availability of data and materials

There is no data in this manuscript.

Declarations

Ethics approval and consent to participate

Not applicable.

Consent for publication

Yes.

Competing interests

The authors declare that they have no competing interests.

Received: 6 March 2021 Accepted: 13 April 2021

Published online: 01 May 2021

References

- Möller CT, Schoonbee CG, Rosendorff C. Haemodynamics of cardiac tamponade during various modes of ventilation. *Brit J Anaesthesia*. 1979; 51(5):409–15.
- Armstrong WF, Schilt BF, Helper DJ, Dillon JC, Feigenbaum H. Diastolic collapse of the right ventricle with cardiac tamponade: an echocardiographic study. *Circulation*. 1982;65(7):1491–6. <https://doi.org/10.1161/01.CIR.65.7.1491>.
- Manyari DE, Kostuk WJ, Purves P. Effect of pericardiocentesis on right and left ventricular function and volumes in pericardial effusion. *Am J Cardiol*. 1983;52(1):159–62. [https://doi.org/10.1016/0002-9149\(83\)90088-7](https://doi.org/10.1016/0002-9149(83)90088-7).
- Georghiou GP, Stamler A, Sharoni E, Fichman-Horn S, Berman M, Vidne BA, et al. Video-assisted thoracoscopic pericardial window for diagnosis and management of pericardial effusions. *Ann Thorac Surg*. 2005;80(2):607–10. <https://doi.org/10.1016/j.athoracsur.2005.02.068>.
- O'Brien PK, Kucharczuk JC, Marshall MB, Friedberg JS, Chen Z, Kaiser LR, et al. Comparative study of subxiphoid versus video-thoracoscopic pericardial "window". *Ann Thorac Surg*. 2005;80(6):2013–9. <https://doi.org/10.1016/j.athoracsur.2005.05.059>.
- Casós SR, Richardson JD. Role of thoracoscopy in acute management of chest injury. *Curr Opin Crit Care*. 2006;12(6):584–9. <https://doi.org/10.1097/MCC.0b013e328010b833>.
- Mack MJ, Landreneau RJ, Hazelrigg SR, Acuff TE. Video thoracoscopic management of benign and malignant pericardial effusions. *Chest*. 1993; 103(4 Suppl):390S–3. https://doi.org/10.1378/chest.103.4_Supplement.390S.
- Piehlér JM, Pluth JR, Schaff HV, Danielson GK, Orszulak TA, Puga FJ. Surgical management of effusive pericardial disease. Influence of extent of pericardial resection on clinical course. *J Thorac Cardiovasc Surg*. 1985;90(4): 506–16. [https://doi.org/10.1016/S0022-5223\(19\)38563-0](https://doi.org/10.1016/S0022-5223(19)38563-0).
- Jama G, Scarci M, Bowden J, Marciniak S. Palliative treatment for symptomatic malignant pericardial effusion. *Interact Cardiovasc Thorac Surg*. 2014;19:1019–26.

Publisher's Note

Springer Nature remains neutral with regard to jurisdictional claims in published maps and institutional affiliations.

Ready to submit your research? Choose BMC and benefit from:

- fast, convenient online submission
- thorough peer review by experienced researchers in your field
- rapid publication on acceptance
- support for research data, including large and complex data types
- gold Open Access which fosters wider collaboration and increased citations
- maximum visibility for your research: over 100M website views per year

At BMC, research is always in progress.

Learn more biomedcentral.com/submissions

