

LETTER TO THE EDITOR

Open Access

Unsatisfying mitral valve repair? The “Loop method”: a lifebelt to grab



Claudia Loardi^{1*} and Marco Zanobini²

Abstract

Intra-operative mitral valve repair failure is a common condition in patients with complex myxomatous disease requiring aortic re-clamping and application of a fast and easy surgical technique to correct the residual imperfection. Herein we describe a reproducible method of artificial chord reconstruction which preserves the previous accomplished acts and allows for accurate chordal length measurement basing on the annuloplasty as the reference level.

Keywords: Mitral regurgitation, Mitral valve repair, Artificial chords

Introduction

Over the last few decades, a better understanding of the structure, function and pathology of the mitral valve (MV) improved the surgical results associated with degenerative MV repair, resulting in excellent long-term survival and freedom from reoperation [1]. Currently, several well-described repairing approaches for anterior and posterior leaflet prolapse are available, including both resectional and non-resectional (respect philosophy) techniques [2].

The respect paradigm for the reconstruction of the leaflet prolapse is mainly based on neochordal implantation procedure, whose critical point is represented by the assessment of artificial chordae proper length. Although various manoeuvres have been described to ensure safe and reproducible results [3], this step remains intuitive and based on personal experience [4]. Especially in case of intra-operative reconstruction failure for complex disease, the surgeon must choose the most appropriate tool among all the available strategies to correct the residual defect.

We report a simple method of neochordae placement and height adjustment using the prosthetic annulus as

the reference point to correct a peri-operative detected unsatisfying MV repair.

Technique

Following MV reconstruction performed with surgeon's preferred technique and annuloplasty ring placement, valve competency is statically tested by injecting saline into the ventricle; if no residual regurgitation nor scallop prolapse or billowing is elucidated in association with a sufficient and harmonic length of coaptation throughout a whole symmetric coaptation line, the result is optimal and the atriotomy is closed. Nevertheless, one of these situations may exist, thus leading the surgeon to perform additional procedures in order to obtain a perfect continent valve.

The same scenario may occur after intra-operative transoesophageal echocardiographic control detecting an unsatisfying mitral repair requiring re-clamping and valve re-examination.

After detailed MV inspection, the prolapsing or poor coapting leaflets segments are easily identified. As a first step of the operative technique, one or more 4–0 Gore-Tex sutures (W.L. Gore & Associates, Flagstaff, AZ) are placed with a double passage in the appropriate papillary muscle head, oriented longitudinally and including the fibrous tip of the muscle (Fig. 1a). Papillary muscle exposure may be difficult in this phase due to the presence of the ring and of valvular repairing sutures: an

*Correspondence: cloardi@yahoo.it

¹ Department of Cardiac Surgery, Tours University Hospital, 37044 Tours Cedex 9, France

Full list of author information is available at the end of the article



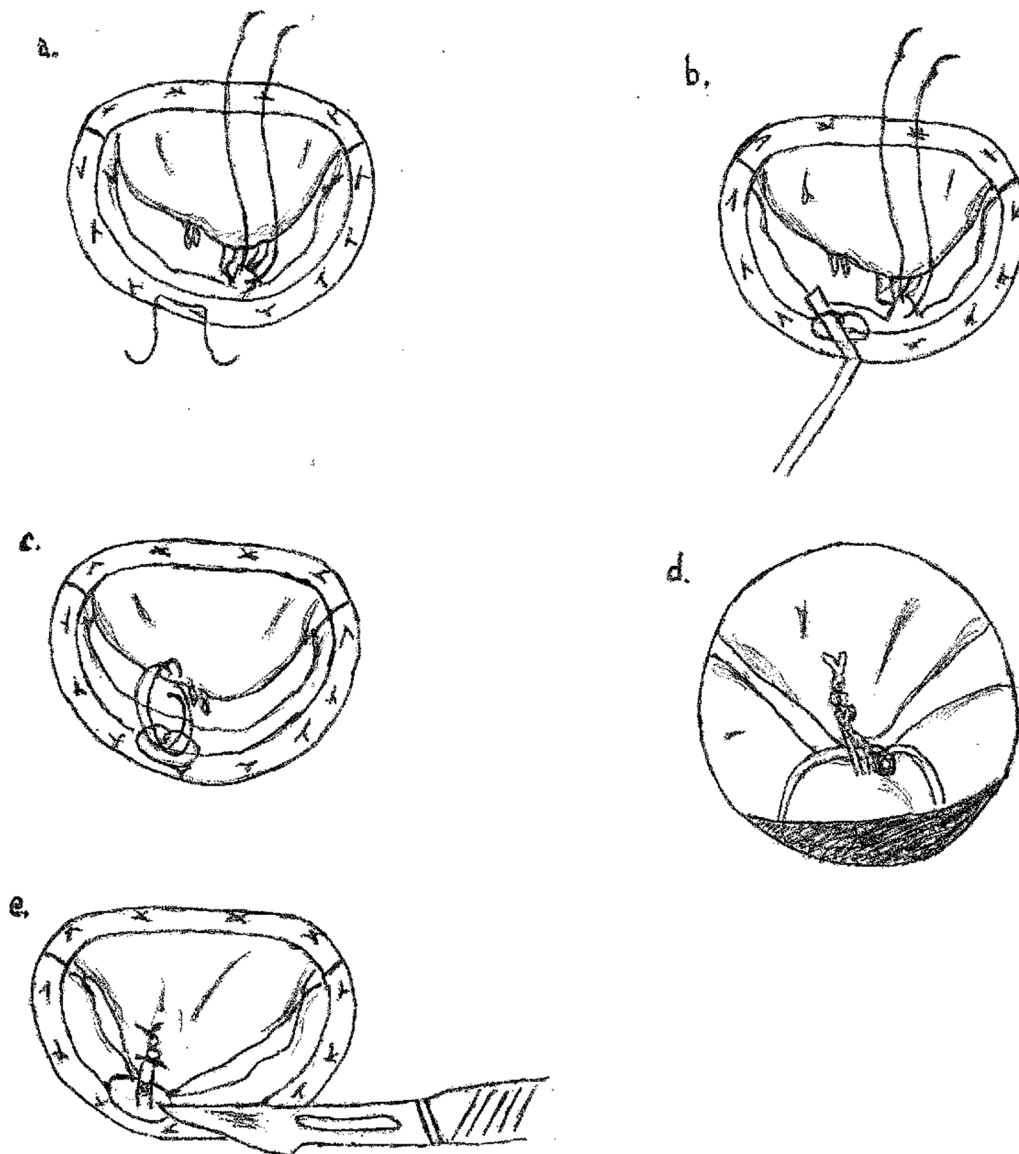


Fig. 1 The “Loop method” technique for neochords length adjustment. **a** Placement of one or more Gore-Tex sutures in the papillary muscle and of an Ethibond stitch in the posterior part of the prosthetic ring. **b** The reference loop is created by tying the annular Ethibond suture leaning on a hook. **c** Both arms of the neochord are passed in the prolapsing area from the ventricular side to the atrial one, then in the loop from the atrium towards the ventricle and finally again into the edge of the prolapsing scallop from the ventricle to the atrium. **d** Knots are tied at the annular level. **e** The reference-loop is cut and the leaflet released

unconnected aspirating cannula or a cylindrical mechanical prosthesis tester are helpful in reclining the anterior leaflet and facilitating the access to the subvalvular apparatus.

A 2/0 Ethibond Excel (Ethicon, Somerville, NJ) suture is passed in the posterior portion of the annuloplasty ring facing (in case of residual anterior leaflet prolapse) or at the basis (for the posterior one) of the guilty scallop and tied leaning on a surgical hook in order to form a loop

representing the reference element for neochord length assessment (Fig. 1a, b). As the posterior ring is chosen as the seat of the guiding stitch, the technique is applicable in case of uncomplete annuloplasty too.

Now, both arms of the previously placed Gore-Tex suture are first passed through the margin of the prolapsing leaflet segment from the ventricular side to the atrial one, then through the reference-loop from the atrium to the ventricle and finally again into the edge of

the prolapsing scallop from the ventricle to the atrium (Fig. 1c). Afterwards, knots are tied at the annular level (Fig. 1d) and the annular reference-loop is cut (Fig. 1e) to release the prolapsing leaflet.

Figure 1a–e describes the case of an anterior residual prolapse but the same procedure is equally applicable to a posterior one.

Such technique of artificial chordae height measurement can similarly be employed as the first approach for MV myxomatous disease repair by placing the loop stitch in the native annulus if the surgeon's preference is to perform annuloplasty at the end of leaflet reconstruction or, on the contrary, in the prosthetic ring if the repairing sequence is neochordae positioning in the papillary muscle—annuloplasty—chords anchorage to the leaflet.

Comment

Nowadays, MV repair includes a large spectrum of native pathologies (and consequently of surgical techniques) varying from the simple P2 prolapse until the Barlow disease with multi-scallop and commissural involvement [5]. In case of complex degenerative regurgitation, the first repairing attempt may result in an intra-operative (during the saline test or at transoesophageal echocardiographic check) unsatisfying result, consisting for instance in a residual limited prolapse or in an insufficient localized coaptation area, a recognized risk factor of long-term plasty failure [6]. Therefore surgeons are faced to the need of completing their previous act in a double difficult situation: a technical uncomfortable setting due to the pre-implanted cumbersome prosthetic ring and leaflet sutures associated to the requirement of performing a short and efficacious correction to limit cross-clamping time.

Our described technique (the “Loop method”) of artificial chord positioning solves both problems exploiting the presence of the annuloplasty ring and following the “respect philosophy”. Although alternative procedures can be employed in similar cases, such as an Alfieri stitch in the prolapsing area which surely represents a simpler solution, our preference is for Gore-Tex neochords since they avoid the danger of increasing trans-valvular gradient (in particular with a pre-existent annuloplasty sized in a different repairing situation) and allow a more physiologic repair.

Certainly, during the application of the technique in a “relooking” setting after a first attempt of mitral repair, great care must be addressed to avoid any interference or impingement between the last added element and the other chords (native or previously inserted). Moreover, as the surgical act may also modify MV set up and scallops interaction by incidentally opening artificial

clefts or by slightly modifying the coaptation line, an accurate final check is essential.

Nevertheless, even if chordal replacement is recognized as a safe, effective and durable mitral reconstruction first line procedure, the well known critical challenge of determining the perfect chords height is topical once again and the codification of an easy height measurement method especially in this re-clamping setting is mandatory. More than 40 strategies are available in medical literature concerning such technical issue and are divided into two groups: those with pre-measured required chordal length and those without [3]. Among those belonging to the last group, our “Loop method” presents some similarities with “The folding leaflet” one [7] but with the advantages of being independent from the assistant's help and of permitting a certain knotting level at the prosthetic annular plane.

The existence of a plethora of techniques addressing the same issue suggests that none of them is reproducible in all hands, thus requiring the description of a standardized method very useful in case of primary plasty failure.

In conclusion, our technique is above all proposed as a simple and accurate “lifeline” rescue strategy (even if it can be applied as a first procedure), whose main interest lies in its fast execution without the need of ring explanation and in a leaflet preserving approach.

Abbreviation

MV: Mitral valve.

Acknowledgements

Not applicable.

Authors' contributions

CL was involved in Concept/Design of the paper and in drafting the manuscript. MZ revised the manuscript. All authors read and approved the final manuscript.

Funding

None.

Availability of data and materials

Not applicable.

Declarations

Ethics approval and consent to participate

Not applicable.

Consent for publication

Not applicable.

Competing interests

The authors have no conflicts of interest to declare.

Author details

¹Department of Cardiac Surgery, Tours University Hospital, 37044 Tours Cedex 9, France. ²Department of Cardiac Surgery, Centro Cardiologico Monzino IRCCS, Università degli Studi di Milano, Milan, Italy.

Received: 25 November 2020 Accepted: 17 September 2021
Published online: 26 September 2021

References

1. Mohty D, Orsulak TA, Schaff HV, Avierinos JF, Tajik JA, Enriquez-Sarano M. Very long-term survival and durability of mitral valve repair for mitral valve prolapse. *Circulation*. 2001;104(12 Suppl 1):i1–7.
2. Perier P, Hohenberger W, Lakew F, Diegeler A. Prolapse of the posterior leaflet: resect or respect. *Ann Cardiothorac Surg*. 2015;4:273–7.
3. Ibrahim M, Rao C, Athanasiou T. Artificial chordae for degenerative mitral valve disease: critical analysis of current techniques. *Interact Cardiovasc Thorac Surg*. 2012;15:1019–32.
4. Adams DH, Kadner A, Chen RH. Artificial mitral valve chordae replacement made simple. *Ann Thorac Surg*. 2001;71:1377–9.
5. Carpentier A. Cardiac valve surgery—the “French correction.” *J Thorac Cardiovasc Surg*. 1983;86:323–37.
6. Adams DH, Rosenhek R, Falk V. Degenerative mitral valve regurgitation: best practice revolution. *Eur Heart J*. 2010;31:1958–67.
7. Garcia-Fuster R, Gil O, Vasquez A, Garcia A, Martinez-Leon J. The folding leaflet: a simple method for neo-chordal repair. *Ann Thorac Surg*. 2010;89:1682–4.

Publisher's Note

Springer Nature remains neutral with regard to jurisdictional claims in published maps and institutional affiliations.

Ready to submit your research? Choose BMC and benefit from:

- fast, convenient online submission
- thorough peer review by experienced researchers in your field
- rapid publication on acceptance
- support for research data, including large and complex data types
- gold Open Access which fosters wider collaboration and increased citations
- maximum visibility for your research: over 100M website views per year

At BMC, research is always in progress.

Learn more biomedcentral.com/submissions

