

CASE REPORT

Open Access



# Surgical correction of total anomalous pulmonary venous return in an adult patient

Yohan Bae, Woo Sung Jang\* and Kyungsub Song

## Abstract

**Background:** Total anomalous pulmonary venous return (TAPVR) is rare congenital heart disease. Most TAPVRs require surgical corrections in the neonatal period and survival to adulthood without surgical correction is extremely rare. Most untreated patients with large atrial septal defects and no pulmonary venous obstruction have pulmonary vascular damage from pulmonary over circulation.

**Case presentation:** 44-year-old TAPVR patient admitted to our medical center. A snowman-shaped heart, including cardiomegaly and an increase in pulmonary blood flow, was seen in the chest X-ray. A large-sized (around 3 cm) atrial septal defect with dilated right atrium, right ventricle, and pulmonary artery was detected on echocardiography. Heart computed tomography was performed for further evaluation, and supra-cardiac type TAPVR without any obstructive lesion was identified.

**Conclusions:** TAPVR in an adult patient is extremely rare, and this patient was treated successfully with surgical correction and is doing well. A sinus rhythm and mild mitral valve regurgitation have remained during 2.5 years of outpatient follow-up.

**Keywords:** TAPVR, Adult congenital heart surgery, Vascular anomalies, Complex congenital heart disease

A 44-year-old man was admitted for acute onset palpitations and dyspnea. On physical examination, clubbed fingers were observed. The patient's oxygen saturation was 89% in room air, and atrial tachycardia was seen on electrocardiography. Blood chemistry evaluation showed elevated liver enzymes (aminotransferase/alanine aminotransferase: 2060/1649 U/L, total bilirubin/ direct bilirubin 4.41/0.84 mg/dL) and amino-terminal pro-brain natriuretic peptide (NT-proBNP) levels up to 6789 pg/mL. A snowman-shaped heart, including cardiomegaly and an increase in pulmonary vasculature, was seen in the chest X-ray (Fig. 1). Cardiomegaly on chest X-ray was detected 23 years ago and noted in his past medical history. However, there was no follow-up.

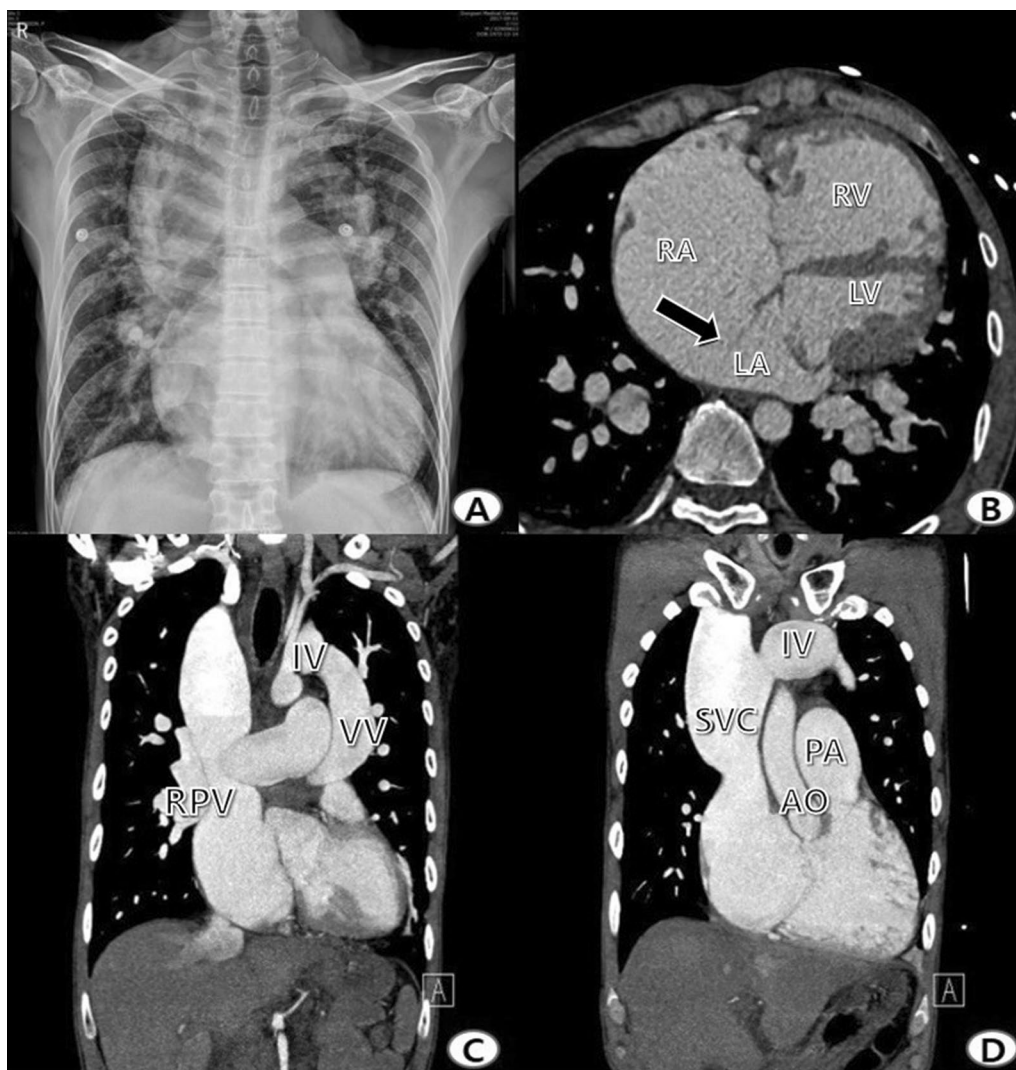A large-sized (around 3 cm) atrial septal defect (ASD) with dilated right atrium, right ventricle, and pulmonary artery was detected on echocardiography. In addition, a D-shaped left ventricle (LV) and severe mitral valve regurgitation were also detected. Sinus rhythm recovered after digitalization and diuretic administration. The mitral valve regurgitation was improved to a mild degree on echocardiography, and the liver enzymes were also normalized. Cardiac computed tomography was performed for further evaluation, and supra-cardiac type total anomalous pulmonary venous return (TAPVR) without any obstructive lesion was identified. The pulmonary venous drainage course, including the superior vena cava was severely dilated. However, the left atrium and left ventricle sizes were adequate (Fig. 1). The pulmonary arterial pressure was 43/22 mmHg (Mean: 29 mmHg) on right heart catheterization (Table 1).

We performed a direct anastomosis of the pulmonary venous confluence to the left atrium and ASD patch

\*Correspondence: whiteuri@dsmc.or.kr

Department of Thoracic and Cardiovascular Surgery, Dongsan Medical Center, Keimyung University School of Medicine, 1035, Dalgubeol-daero, Dalseo-gu, Daegu 42601, Republic of Korea





**Fig. 1** Preoperative chest X-ray and computed tomography (CT). **A** Preoperative chest X-ray. **B** Axial view on CT shows an enlargement of the RA and RV, secundum-type ASD (arrow), and left dislocation of the LA and LV. **C, D** Coronal view on CT shows that the IV is connected to the VV and drains to the SVC. RA, right atrium; RV, right ventricle; ASD, atrial septal defect; LA, left atrium; LV, left ventricle; IV, innominate vein; VV, vertical vein; RPV, right pulmonary vein; SVC, superior vena cava; PA, pulmonary artery; AO, aorta

**Table 1** Preoperative cardiac catheterization data

Site	O2 saturation (%)	Pressure systolic/diastolic pressure (mean), mmHg
Superior vena cava	90.7	
Right atrium	85.4	12/4 (7)
Right ventricle	88.7	43/8 (20)
Pulmonary artery	88.7	43/22 (29)
Left atrium	89.6	12/5 (7)
Aorta	90	100/60 (73)

closure by the transverse sinus approach without total circulatory arrest. The vertical vein was ligated. The cardiopulmonary bypass (CPB) and aortic cross-clamp times were 147 and 61 min, respectively. We also checked the mitral valve morphology. The mitral valve showed diffuse leaflet thickening at the anterior and posterior valves. However, the coaptation margin of the valve leaflet was good. Thus, we did not perform mitral valve surgery. The patient weaned off CPB easily. On postoperative TEE, No turbulence was observed across the anastomosis, and the mitral valve regurgitation was mild. The patient was extubated on postoperative day (POD) 0 and transferred to the general ward on POD 1. He was discharged from

hospital on POD 8 without any symptoms. The patient is doing well. The cardiac rhythm remains in sinus rhythm and transthoracic echocardiography show mild mitral valve regurgitation after 2.5 years of operation (Fig. 2).

## Discussion

TAPVR is a rare anomaly accounting for only 1.5% to 2.2% of congenital heart disease [1]. TAPVR is a cardiac malformation in which all pulmonary veins on either side are not connected to the left atrium, but directly to the somatic vein or the right atrium. Almost all patients with TAPVR present with symptoms of heart failure in the neonatal period, which require early surgical correction. It is unusual to encounter an adult patient with TAPVR due to low survival rate in untreated cases.

According to Talwar et al. [2] in group of 27 patients who underwent surgery for TAPVR at the age of 15–48 years, Unobstructed pulmonary venous drainage, a larger inter-atrial communication, maintenance of vascular resistance and pulmonary pressure closer to normal limits was important factors for survival in unoperated patients with TAPVR. Like this authors believes, Our patient also had mild pulmonary hypertension, supracardiac type TAPVR with non restrictive ASD and absence of pulmonary obstruction. This condition is major factors for long term survival in adult TAPVR patients.

If patients not had pulmonary vascular disease, most patients are able to complete repair. But with severe pulmonary artery hypertension, Right heart decompression such as small interatrial communication, partial closure of the septal defect and unidirectional valve patch, should be performed [3]. All these techniques were left to permit right-to-left shunting

during pulmonary hypertensive crisis. Alternate surgical option had been reported by India group about test protocol for selective ligation of vertical vein [4]. A patent vertical vein functions like an atrial septal defect, when too small noncompliant atrium to accommodate blood flow after surgical repair. But this technique was potential hazard to left-to-right shunt. Especially in pulmonary hypertensive crisis with pulmonary arteriolar constriction, Left-to-right shunt results in lower preload of left ventricle which exacerbates cardiac output reduction.

There are few adult TAPVR patients worldwide. The cases reported previously showed a favorable prognosis in the postoperative phase. However, approximately 10% to 15% of the patients have evidence of late pulmonary vein obstruction, which tends to be recurrent and progressive [5]. In the three years of follow-up after surgery, this patient did not show any complications, including pulmonary venous obstruction or mitral valve regurgitation. However, long-term surveillance and monitoring are required.

## Abbreviations

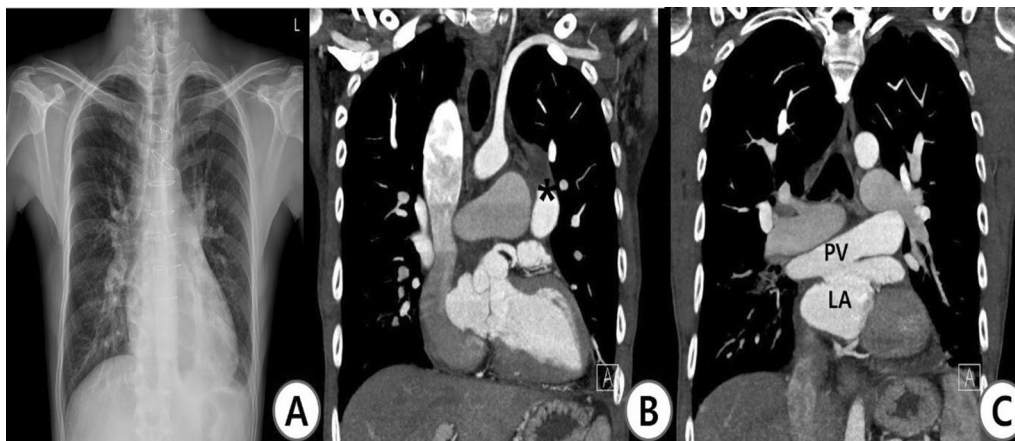
NT-proBNP: NT-amino-terminal pro-brain natriuretic peptide; ASD: Atrial septal defect; LV: Left ventricle; TAPVR: Total anomalous pulmonary vein return; CPB: Cardiopulmonary bypass; POD: Postoperative day.

## Acknowledgements

Not applicable.

## Author contributions

WJ was the operator of this case and the corresponding author of this article. YB was a major contributor in writing the manuscript. KS made critical revisions to the manuscript and collect data. All authors read and approved the final manuscript.



**Fig. 2** Postoperative computed tomography (CT). **A** Chest X-ray at discharge. **B, C** Coronal view on chest CT at 2.5 years after surgery. The PV was connected to the LA. PV, pulmonary vein; LA, left atrium. \*ligated vertical vein

**Funding**

No.

**Availability of data and materials**

Not applicable.

**Declarations****Ethics approval and consent to participate**

All procedures performed in studies involving human participants were in accordance with the ethical standards of the institutional and/or national research committee and with the 1964 Helsinki declaration and its later amendments or comparable ethical standards.

**Competing interests**

The authors declare that they have no competing interest.

Received: 13 June 2022 Accepted: 20 August 2022

Published online: 19 September 2022

**References**

1. Hoffman JI, Kaplan S. The incidence of congenital heart disease. *J Am Coll Cardiol.* 2002. [https://doi.org/10.1016/s0735-1097\(02\)01886-7](https://doi.org/10.1016/s0735-1097(02)01886-7).
2. Talwar S, Choudhary SK, Reddy S, et al. Total anomalous pulmonary venous drainage beyond childhood. *Interact Cardiovasc Thorac Surg.* 2008;7:1058–61. <https://doi.org/10.1510/icvts.2008.186734>.
3. Talwar S, Keshri VK, Choudhary SK, et al. surgical strategies for patients with congenital heart disease and severe pulmonary hypertension in low/middle-income countries. *Heart Asia.* 2015;7(2):31–7. <https://doi.org/10.1136/heartasia-2015-010645>.
4. Chowdhury UK, Subramaniam KG, Joshi K, et al. Rechanneling of total anomalous pulmonary venous connecton with or without vertical vein ligation: results and guidelines for candidate selection. *J Thorac Cardiovasc Surg.* 2007;133(5):1286–94. <https://doi.org/10.1016/j.jtcvs.2006.08.010>.
5. Ashfaq A, Shah N, Khan MZ, Atiq M, Amanullah MM. Successful surgical intervention of total anomalous pulmonary venous drainage in the third decade of life. *Ann Med Surg.* 2013. [https://doi.org/10.1016/s2049-0801\(13\)70039-6](https://doi.org/10.1016/s2049-0801(13)70039-6).

**Publisher's Note**

Springer Nature remains neutral with regard to jurisdictional claims in published maps and institutional affiliations.

Ready to submit your research? Choose BMC and benefit from:

- fast, convenient online submission
- thorough peer review by experienced researchers in your field
- rapid publication on acceptance
- support for research data, including large and complex data types
- gold Open Access which fosters wider collaboration and increased citations
- maximum visibility for your research: over 100M website views per year

At BMC, research is always in progress.

Learn more [biomedcentral.com/submissions](https://biomedcentral.com/submissions)

