Kato *et al. Journal of Cardiothoracic Surgery* (2024) 19:13
https://doi.org/10.1186/s13019-024-02495-3

Journal of
Cardiothoracic Surgery

CASE REPORT

Open Access

Rapid expansion of a left atrial myxoma caused by acute multiple internal hemorrhages: a case report and literature review

Takayoshi Kato[1*], Etsuji Umeda[1], Natsuko Suzui[2], Ryo Fujii[1], Hiroki Ogura[1], Osamu Sakai[1], Katsuya Shimabukuro[1] and Kiyoshi Doi[1]

Abstract

Background Left atrial myxoma is the most common benign tumor, with the growth rate remaining unknown because specific symptoms do not present until the tumor grows to a certain size. Early surgical management is performed in most cases once it is detected by physicians. Despite cardiac myxomas commonly being perceived as slow-growing tumors, rapid enlargement of myxomas has been reported.

Case presentation A 64-year-old woman was referred to our hospital with a diagnosis of a left atrial tumor. The pointed tumor changed morphologically in a few hours, and her respiratory condition, which had been normal at admission, suddenly deteriorated. Emergent surgery was performed, and the diagnosis was myxoma with multiple intratumor massive hematomas. The patient recovered uneventfully and was discharged on postoperative day 12 without any complications.

Conclusions We report an extremely rare case of left atrial myxoma rapidly expanded due to acute multiple hemorrhages within itself. Massive internal hemorrhage alters the size, shape, and fragility of the tumor. We should recognize the potential risk of internal hemorrhage that may lead to acute deterioration of the so-called "slow-growing benign" tumors, such as myxomas.

Keywords Left atrial myxoma, Internal hemorrhage, Rapid growing, SAR-CoV-2 vaccination

Background

Left atrial (LA) myxomas are the most common primary heart tumors and often cause arterial embolism, cardiac flow obstruction, and sudden death. Therefore, early surgical management for LA myxomas is performed in most cases despite they are commonly perceived as slow-growing benign tumors. However, several authors have described rapid growth of LA myxomas. The causation is still unknown, but acute hemorrhage within the tumor is probably one of the important factors for rapid growth of myxomas [1–4].

Here, we report a surgically treated case of LA myxoma with acute multiple internal hemorrhages that resulted in rapid morphological collapse and symptomatic deterioration.

Case presentation

A 64-year-old woman without any significant medical history was referred to our hospital with a diagnosis of an LA tumor.

She visited her primary clinic complaining of fatigue on light effort and stated her symptoms had been recognized after receiving her fifth vaccination for severe acute

*Correspondence:
Takayoshi Kato
takayoshi.ninelives@gmail.com
[1] Department of Cardiovascular Surgery, Gifu University Hospital, 1-1 Yanagido, Gifu City, Gifu 501-1193, Japan
[2] Department of Pathology, Gifu University Hospital, Gifu, Japan

respiratory syndrome coronavirus 2 (SARS-CoV-2) four weeks earlier. Her vital signs at that time were within normal limits except her pulse rate was at a regular rhythm of 121 per minute. Echocardiography performed by the physician in the primary clinic revealed an oval tumor measuring approximately 25×35 mm in the LA. There was a 12-mm round hypoechoic area within the tumor. The patient had no symptoms at that time. Therefore, she drove her own car to our hospital following the instructions of the physician. Upon arrival at our hospital, she stated no symptoms at rest. Her vital signs on arrival were a blood pressure of 140/82 mmHg, a regular pulse rate of 142 per minute, and 98% oxygen saturation in room air.

Transthoracic echocardiography (TTE) performed at our hospital revealed a mobile myxomatous LA tumor approximately 40×50 mm in size originating from the LA septum. There was a 20×30-mm oval cystic lesion within the tumor. The tumor and its internal cystic lesion were obviously expanded compared to those in the image captured at the primary clinic two hours earlier (Fig. 1). The mitral valve obstruction due to the expanding tumor was remarkable. Therefore, we conducted emergency surgery for tumor resection. During preparations for the surgery, the patient started complaining of dyspnea and her oxygen saturation gradually decreased to 88% under 100% of oxygen.

In the operating room, transesophageal echocardiography (TEE) disclosed that the tumor had been morphologically changing rapidly over time. Longitudinal expansion and lobing changes were remarkable (Fig. 2). Under cardiopulmonary bypass and cardioplegic arrest, a transseptal supra-atrial incision was made. The tumor pedicle was attached to the inter-atrial septum and the free LA wall. Resection of the tumor with the surrounding atrial wall and reconstruction of the defects using a bovine patch were performed. The myxomatous mass with multiple protruding hematomas measured 50×38 mm. Multiple myxomatous tissue defects were formed due to fresh intratumor bleeding (Fig. 3). Microscopic findings showed spindle-shaped cells and hyperchromatic nuclei segregated by abundant myxomatous stroma. Hemosiderin pigmentation and the presence of erythrocytes in the myxoid matrix indicated chronic and fresh bleeding. The myxomatous capsule right above the site of multiple hemorrhages was extremely thin (Fig. 4). The postoperative recovery was uneventful, and the patient was discharged on postoperative day 12 without any complications.

Discussion and conclusions

In general, cardiac myxomas are recognized as slow-growing benign tumors. However, because of their potentially life-threatening manifestations, such as arterial embolism and cardiac flow obstruction, early surgical management has become a common practice in recent years.

The growth rate of LA myxomas was first described in 1987 [5, 6] and has been reported in several studies since then. After searching the English literature on the study of the growth rate of primary LA myxoma, we found 16 reports mentioning the growth rate [5–20] (Table 1). The median value and range of growth rate were 3.5 mm/month and 0–28.3 mm/month, respectively. Walpot et al.

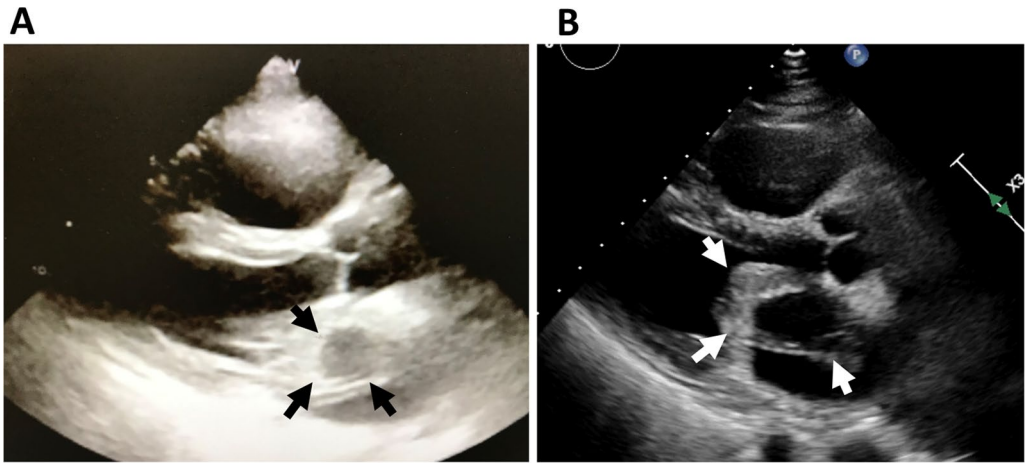

Fig. 1 Transthoracic echocardiogram in the parasternal long-axis view. **A** An image captured by the physician in the primary clinic two hours before admission to our hospital. An oval tumor (arrows) measuring about 25×35 mm in the left atrium was revealed. There was a 12-mm round hypoechoic area within the tumor. **B** An image taken upon admission to our hospital. A tumor (arrows) approximately 40×50 mm in size included a 20×30-mm-sized cystic lesion within it. The tumor and its internal cystic lesion were obviously expanded compared to those in the image captured in the primary clinic two hours earlier

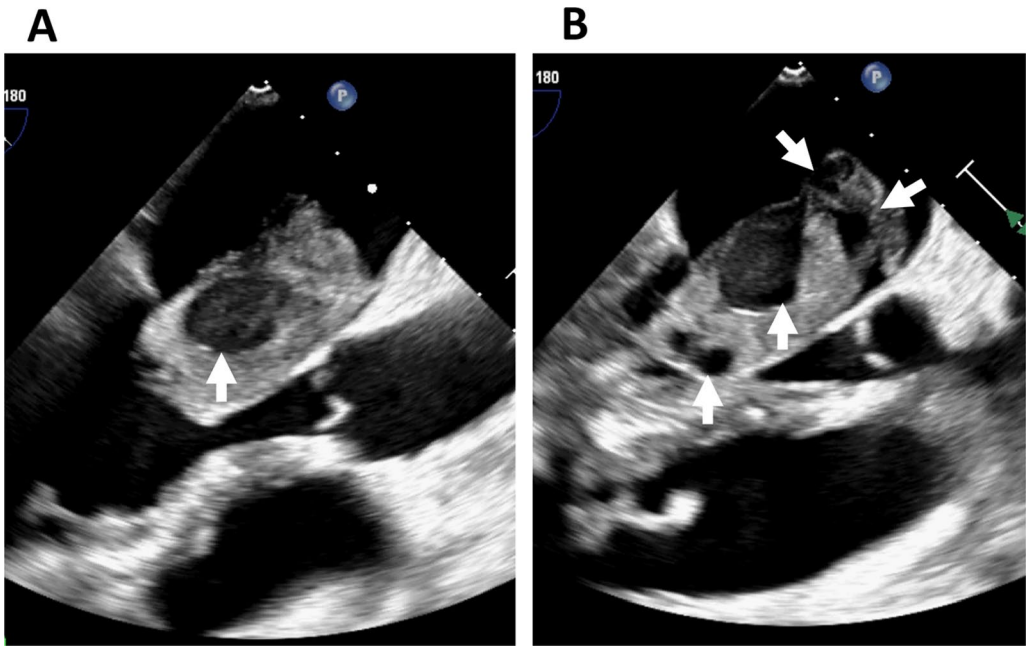

Fig. 2 Transesophageal echocardiography images at 127 degrees. **A** At the insertion of the probe. **B** Just before establishing cardiopulmonary bypass. The tumor deformed rapidly morphologically during the operation. Flattening and lobing changes were remarkable. Small cystic formations just below the lobes were increased (arrows)

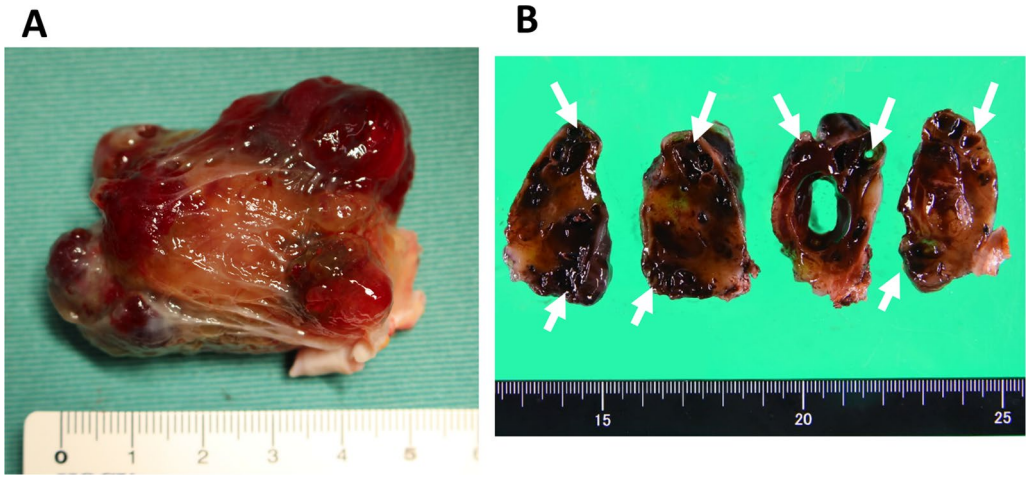

Fig. 3 Specimen. **A** The gross appearance showing myxomatous with multiple protruding hematomas. **B** Fixed specimen showing multiple tissue defects formed by intratumor hematomas (arrows). These hemorrhages were recognized as cystic lesions on echocardiography

[14] conducted a literature review and disclosed a "rapid-growth rate" of LA myxoma averaging 4.9 mm/month. Regarding its growth direction, Karlof et al. [21] assumed that myxomas grow in a linear fashion. However, in reality, growth may be exponential such that the estimated growth rate would vary depending on when the diagnosis is made. Iga et al. [11] reported a case in which the horizontal and longitudinal distances of the tumor increased, while the size of the base remained unchanged.

Rubio Alvarez et al. [16], based on the case they encountered, noted that the initial period of tumor growth can be quite rapid. In contrast, Lane et al. [10] stated that LA myxoma may exhibit a quiescent phase or at least a heterogeneous growth rate. Though reporting bias must be considered, these presentations might support the speculation that myxomas grow faster than they are considered to.

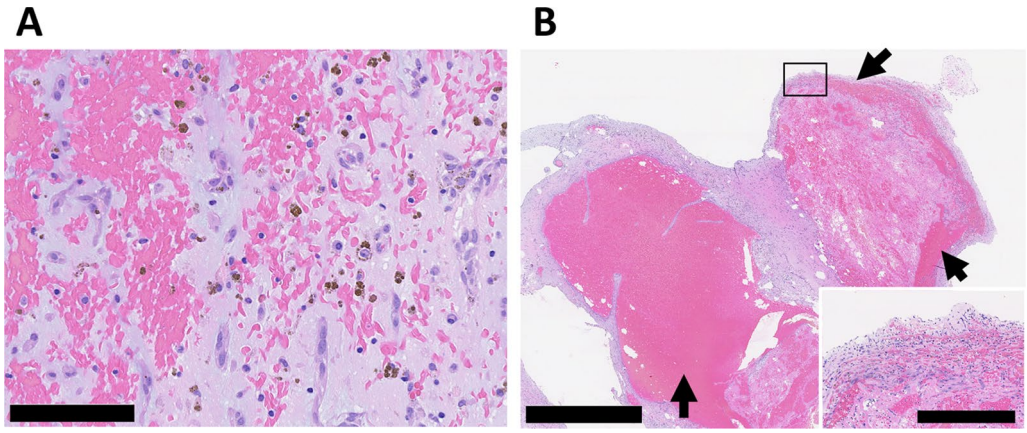

Fig. 4 Hematoxylin and eosin-stained sections of the tumor. **A** Spindle-shaped cells and hyperchromatic nuclei segregated by abundant myxomatous stroma. Hemosiderin pigmentation and the presence of erythrocytes in the myxoid matrix indicated chronic and fresh bleeding (bar = 100 μm). **B** The myxomatous capsule right above the multiple hemorrhages was extremely thin (square) (bar = 2500 μm). The inset shows a thin capsule under high magnification (bar = 500 μm). Arrows indicate hemorrhages

Table 1 Reported growth rate of left atrial myxoma

Author	Year	Age (y)/sex	Size first echo (mm)	Size last echo (mm)	Interval (months)	Growth rate (mm/months)
Marinissen et al. [5]	1987	65 /male	Absent	60 × 40	18	3.3
Roudaut et al. [6]	1987	45/male	Absent	60 × 40	7	8.5
Ahern et al. [7]	1989	76/male	Absent	25 × 40	17	2.3
Pochi et al. [8]	1991	62/female	Absent	75 × 50 × 35	17	4.4
Rey et al. [9]	1993	74/female	Absent	45 × 29 × 39	27	1.7
Lane et al. [10]	1994	71/male	29 × 21	28 × 21	28	0
Iga et al. [11]	1997	57/male	15 × 13	38 × 36	18	2.1
Kay and Chow [12]	2002	71/male	40 × 46	40 × 47	180	0
Ullah and McGovern [13]	2005	89/male	NA	NA	79	0.04
Walpot et al. [14]	2010	65/female	Absent	44 × 40	12	3.7
Vazir and Douthwaite [15]	2011	62/female	Absent	26.7 × 10	12	2.2
Alvarez et al. [16]	2013	60/male	10 × 10	20 × 20	3	6.6
Kim and Kim [17]	2019	75/female	Absent	38 × 27	3	12.6
Strecker et al. [18]	2019	65/male	Absent	12 × 17 × 17	12	1.4
Longhitano et al. [19]	2021	71/female	10 × 6	36 × 29	8	28.3
Goodwin et al. [20]	2021	32/female	NA	NA	4.5	7.7

NA not applicable

In our case, although there were no data concerning the growth rate of the myxoma, it is worth mentioning that the tumor demonstrated acute multiple hemorrhages within itself, which were recognizable as multiple cystic lesions during echocardiography. The pathological study revealed massive fresh central hemorrhage and lobular subcapsular bleeding accompanying the old hemorrhage. Roskell and Biddolph [2] have documented that clinical cases in which myxomas have grown rapidly are probably due to changes in the intercellular matrix rather than cellular proliferation. In our case, multiple intratumor hemorrhages pushed the parenchyma outward, and the outer layer of the myxoma was extremely thin. TEE proved the rapid longitudinal expansion and lobing changes over time.

The massive internal bleeding of myxomas, like in our case, is an extremely rare manifestation reported in English literature [1, 3, 4]. These reports describe rapid clinical deterioration and a cystic lesion within the myxoma. However, multiple cystic lesions due to intramyxoma hemorrhage have not been reported previously. In our review of case reports mentioning obvious

growth rates, we were unable to find reports on myxomas with cystic lesions. In other words, myxomas with massive bleeding might show extremely quick growth. We believe that this report is the first to present a highly uncommon occurrence of acute multiple internal hematomas, accompanied by a notably accelerated morphological transformation and collapse in a myxoma, induced by acute extensive intratumoral bleeding.

The pathological examination of the tumor showed abnormally dilated vessels around the tumor stalk, and their disruption was thought to be the cause of internal hemorrhages. However, the cause of the bleeding within the myxoma is unknown. The patient denied any history of chest trauma or bleeding tendency. Her laboratory test results did not reveal any abnormality in coagulation and fibrinolytic system. Recently, rare cases of acute pituitary tumor hemorrhage after SARS-CoV-2 vaccination have been reported [22, 23]]. Regarding the current case, four weeks before emergent surgery, the patient received the fifth SARS-CoV-2 vaccination and noticed that she felt abnormally fatigued on light exertion one week after the inoculation. Although we cannot confirm the correlation between intratumor bleeding and vaccination, this case may also call attention to possible intratumor hemorrhage after SARS-CoV-2 vaccination.

In conclusion, we report an extremely rare case of LA myxoma rapidly expanded due to acute multiple internal hemorrhages. Massive internal hemorrhage changes tumor size, shape, and fragility. We should recognize the potential risk of internal hemorrhage that may lead to acute deterioration of the so-called "slow-growing benign" tumors, such as myxoma.

Abbreviations

LA	Left atrial
SARS-CoV-2	Severe acute respiratory syndrome coronavirus 2
TTE	Transthoracic echocardiography
TEE	Transesophageal echocardiography

Acknowledgements
We would like to thank Editage (www.editage.com) for English language editing.

Author contributions
TK drafted the manuscript. EU, RF, HO, OS, KS, and KD participated in the revision of the manuscript for intellectual content. NS made pathological sections and pictures. All authors read and approved the final manuscript.

Funding
We received neither funding nor sponsorship for this study nor for publication of this article.

Availability of data and materials
Data sharing is not applicable to this article as no datasets were generated or analyzed.

Declarations

Ethics approval and consent to participate
Written informed consent was obtained from the patient to participate in this study.

Consent for publication
Written informed consent for publication of clinical details and clinical images was obtained from the patient. A copy of the consent form is available for review by the Editor of the journal.

Competing interests
The authors declare no competing interests.

Received: 8 May 2023 Accepted: 14 January 2024
Published online: 20 January 2024

References

1. Sonker U, Kloppenburg GTL, Knoop EA, Seldenrijk CA, Morshuis WJ. Emergency surgery for acute mitral valve obstruction resulting from hemorrhage within a left atrial myxoma. Ann Thorac Surg. 2009;87(2):636–8. https://doi.org/10.1016/j.athoracsur.2008.06.019.
2. Roskell DE, Biddolph SC. Proliferating cell nuclear antigen expression grossly over-estimates cellular proliferation in cardiac myxomas. Eur J Med Res. 1999;4(3):105–6.
3. Walker AH, Wilkinson JM, Goiti JJ. Acute bicaval obstruction as a result of intracapsular haemorrhage in a right atrial myxoma: report of a case. Eur J Cardiothorac Surg. 1997;11(4):779–81. https://doi.org/10.1016/s1010-7940(96)01069-x.
4. Alam MB, Quader SA, Rahim AMA, Bari MS, Khan ZH, Hassan MK. Emergency surgery for acute mitral valve obstruction resulting from rapidly enlarging left atrial myxoma. Cardiovasc J. 2016;8(2):155–7.
5. Marinissen KI, Essed C, de Groot C, Schelling A, Hagemeijer F. Growth rate of left atrial myxoma. Development of a symptomatic left atrial myxoma less than two years after coronary artery bypass grafting. Chest. 1987;92(5):941–2. https://doi.org/10.1378/chest.92.5.941.
6. Roudaut R, Gosse P, Dallocchio M. Rapid growth of a left atrial myxoma shown by echocardiography. Br Heart J. 1987;58(4):413–6. https://doi.org/10.1136/hrt.58.4.413.
7. Ahern T, Chandrasekaran K, Mintz GS, Ross J. Detection of growth of an atrial myxoma after aortic valve replacement. Am Heart J. 1989;118(5 Pt 1):1062–3. https://doi.org/10.1016/0002-8703(89)90247-0.
8. Pochis WT, Wingo MW, Cinquegrani MP, Sagar KB. Echocardiographic demonstration of rapid growth of a left atrial myxoma. Am Heart J. 1991;122(6):1781–4. https://doi.org/10.1016/0002-8703(91)90303-y.
9. Rey MJ, Tamm C, Faidutti B, Luthy P, Unger PF. Growth rate of primary left atrial myxoma. Eur Heart J. 1993;14(8):1146–7. https://doi.org/10.1093/eurheartj/14.8.1146.
10. Lane GE, Kapples EJ, Thompson RC, Grinton SF, Finck SJ. Quiescent left atrial myxoma. Am Heart J. 1994;127(6):1629–31. https://doi.org/10.1016/0002-8703(94)90398-0.
11. Iga K, Izumi C, Konishi T. Rapid growth of a left atrial myxoma. Serial two-dimensional echocardiographic observation over eighteen months. Int J Cardiol. 1997;61(1):85–7. https://doi.org/10.1016/s0167-5273(97)00109-5.
12. Kay JFL, Chow WH. Long-term survival of quiescent left atrial myxoma in an elderly patient. Am J Geriatr Cardiol. 2002;11(3):165–8.
13. Ullah W, McGovern R. Natural history of an atrial myxoma. Age Ageing. 2005;34(2):186–8. https://doi.org/10.1093/ageing/afi010.
14. Walpot J, Shivalkar B, Rodrigus I, Pasteuning WH, Hokken R. Atrial myxomas grow faster than we think. Echocardiography. 2010;27(10):E128–31. https://doi.org/10.1111/j.1540-8175.2010.01186.x.
15. Vazir A, Douthwaite H. Rapidly growing left atrial myxoma: a case report. J Med Case Rep. 2011;5:417. https://doi.org/10.1186/1752-1947-5-417.
16. Rubio Alvarez J, Martinez de Alegria A, Sierra Quiroga J, Adrio Nazar B, Rubio Taboada C, Martinez Comendador JM. Rapid growth of left atrial myxoma after radiofrequency ablation. Tex Heart Inst J. 2013;40(4):459–61.

17. Kim TY, Kim KH. Rapidly growing intra-cardiac mass mimicking a local recurrence of lung cancer or a thrombus in the left atrium. Heart Surg Forum. 2019;22(5):E317–8. https://doi.org/10.1532/hsf.2479.
18. Strecker T, Nooh E, Marwan M, Agaimy A. Rapidly growing cardiac myxoma diagnosed within 1 year after unremarkable prior cardiac imaging. J Card Surg. 2019;34(12):1645–6. https://doi.org/10.1111/jocs.14314.
19. Longhitano A, Wong J, O'Sullivan P, Yao J, Teo E, Brooks M. The life of a myxoma—transoesophageal images of the progressive growth of a myxoma over a 19-month period. Heart Lung Circ. 2021;30:S208.
20. Goodwin S, Ternouth I, Pirone F. The rapid growth rate of a left atrial myxoma occurring between two TOEs: a case report and literature review. Heart Lung Circ. 2021;30:S83. https://doi.org/10.1016/j.hlc.2021.05.061.
21. Karlof E, Salzberg SP, Anyanwu AC, Steinbock B, Filsoufi F. How fast does an atrial myxoma grow? Ann Thorac Surg. 2006;82(4):1510–2. https://doi.org/10.1016/j.athoracsur.2005.11.014.
22. Piñar-Gutiérrez A, Remón-Ruiz P, Soto-Moreno A. Case report: pituitary apoplexy after COVID-19 vaccination. Med Clin. 2022;158(10):498–9. https://doi.org/10.1016/j.medcli.2021.09.028.
23. Roncati L, Manenti A. Pituitary apoplexy following adenoviral vector-based COVID-19 vaccination. Brain Hemorrhages. 2023;4(1):27–9. https://doi.org/10.1016/j.hest.2022.04.002.

Publisher's Note