

CASE REPORT

Open Access

Surgical treatment of innominate artery and aortic aneurysm: a case report and review of the literature

Erdinc Soylu¹, Leanne Harling^{1,3*}, Hutan Ashrafian¹, Vania Anagnostakou², Dimitris Tassopoulos², Christos Charitos², John Kokotsakis² and Thanos Athanasiou¹

Abstract

Innominate artery (IA) aneurysms represent 3% of all arterial aneurysms. Due to the risk of thromboembolic complications and spontaneous rupture, surgical repair is usually recommended on an early elective basis. We present the case of 81-year-old Caucasian male presenting with atypical anterior chest pain secondary to a large innominate artery aneurysm who underwent successful open surgical repair at our institution. In our experience, open correction via median sternotomy with extension into the right neck provides excellent exposure and facilitates rapid reconstruction with good short and long-term outcomes. Minimally invasive and endovascular approaches provide emerging alternatives to open IA aneurysm repair, however further research is required to better define optimal patient selection criteria and determine the long-term outcomes of these novel therapies.

Keywords: Brachiocephalic trunk, Aneurysm, Surgery

Background

Aneurysms of innominate artery (IA) make up approximately 3% of all arterial [1] and 3% of all supra-aortic vessel aneurysms [2]. The majority of IA aneurysms are atherosclerotic in aetiology [3], however alternative causes include syphilis, tuberculosis, Kawasaki's disease, Takayasu's arteritis, Behçets disease, connective tissue disorders and angiosarcoma.

Aneurysms of the IA commonly present secondary to local compression, thrombosis or distal embolization, giving rise to a diverse range of symptoms including dyspnoea, dysphagia, hoarseness, facial and upper limb oedema, chest pain, digital ischaemia, right hemispheric symptoms, amorosis fugax, vertebrobasilar syndrome, and rarely the presence of a pulsatile anterior thoracic mass [4].

Untreated IA aneurysms are liable to rupture, compress nearby viscera or give rise to cerebrovascular embolism [3]. Rupture is the most threatening presentation occurring in approximately 11% of all patients [5]. The

risk of rupture is however more likely following trauma or in patients with underlying connective tissue disease [5,6], and early repair by means of open surgery or endovascular therapy is therefore advocated in patients with symptomatic disease, associated aortic arch aneurysms, saccular aneurysms or isolated asymptomatic aneurysms of >3cm diameter [5].

Over the recent years, there has been an increase in the number of reports of endovascular innominate aneurysm repair however the majority of cases are still treated using an open surgical technique via median sternotomy with or without extension to right neck (Table 1).

We present a case of IA aneurysm involving the aortic arch treated via an open approach, and review the current literature on the role of open surgical and minimally invasive interventions for the treatment of IA aneurysms.

Case presentation

A 81-year-old Caucasian male with hypertension was admitted to our hospital with atypical anterior chest pain. History and physical examination were unremarkable. However, transthoracic echocardiography demonstrated an aneurysm of the ascending aorta (5.4cm) with mild aortic regurgitation and an LVEF of 50%. Computerized

* Correspondence: Leanne.harling@imperial.ac.uk

¹Department of Surgery and Cancer, Imperial College London, London, UK

³Department of Surgery and Cancer, Imperial College London, 10th floor QEOM Building, St. Mary's Hospital, Praed Street, London W2 1NY, UK

Full list of author information is available at the end of the article

Table 1 Summary of observed short and long-term complications

Access route	Study	Year	Elective: Emergency	Length of stay	Short-term outcomes (<30 days)			Long-term outcomes (>30 days)		
					Mortality	Morbidity	Graft patency	Morbidity	Graft patency	Follow-up
Endovascular										
	Angiletta [12]	2012	1:0	-	0	-	-	-	Patent	Alive and developed an aneurysm of the right carotid artery bifurcation at 96 months
	Taha [15]	2010	1:0	-	-	-	Patent	-	Patent	-
	Puech-Leao [16]	2001	1:0	7	0	-	-	-	Patent	Alive and symptom free at 24 months
	Park [17]	2001	1:0	-	-	-	Patent	-	Patent	-
Hybrid endovascular and sternotomy										
	Mellisano [13]	2004	1:0	8	0	Atrial fibrillation, cardiac arrest, pulmonary effusion	Patent	-	-	Alive and symptom free at 3 months
Cervical approach										
	Takach [18]	2007	1:0	-	0	-	-	-	-	-
Partial median sternotomy										
	MacLean [19]	2007	1:0	-	-	-	-	-	-	-
	Mori [20]	2004	1:0	-	-	-	-	-	-	-
	Lane [21]	1951	1:0	-	0	Phrenic nerve damage, fever	-	Muscle atrophy/weakness	-	-
Full median sternotomy										
	Constenla [11]	2012	1:0	-	0	Respiratory failure, pneumonia	Patent	-	-	Alive and symptom free at 12 months
	Oswal [22]	2011	1:0	-	0	-	-	-	-	Alive and symptom free at 12 months
	Lu [14]	2011	1:0	-	0	-	-	-	-	Alive at 20 months
	Yuan [23]	2009	1:0	-	-	Stroke	-	-	-	-
	Da Col [24]	2007	1:0	12	-	-	Patent	-	-	-
	Oruganti [25]	2006	1:0	-	-	-	Patent	-	-	-
	Saito [26]	2005	1:0	-	-	-	-	-	-	-
	Kieffer [5]	2001	23:4	-	3	Neurological deficits (2), dysphonia (3), haemorrhage (1), artificial ventilation (5), multiple organ failure (2)	Patent (21), unknown (3)	Dysphonia (1), mediastinitis (1)	Patent (14), unknown (3)	7 deaths (cancer=3, cardiac=2, accident =1, unknown=1) during 85 months (3–194)

Table 1 Summary of observed short and long-term complications (Continued)

Chiappini [27]	2001	1:0	-	0	-	-	-	Patent	Alive at 6 months
Guibaud [28]	2001	0:1	-	0	-	-	Subclavian steal syndrome	-	-
Najafi [29]	1999	1:0	6	-	-	-	-	-	-
Villegas-Cabello [30]	1996	1:0	-	-	-	-	-	-	-
Adkins [31]	1993	1:0	20	-	-	-	-	-	-
Bower [3]	1991	6:0	-	0	Atelectasis (1), pneumonitis (1), brain stem infarct (1)	-	Stroke (1)	-	3 late deaths (cancer=1, stroke=1, vasculitis and heart disease=1), lost to follow up (1), unknown (1). 5 year survival=62.5%
Thomas [32]	1972	1:0	-	1	Thromboembolism	-	-	-	-
Combined full median sternotomy and cervical approach									
Ketonen [33]	1983	1:0	-	0	Wound haematoma of femoral incision	-	-	-	Alive and symptom free at 108 months
		1:0	-	0	-	-	-	Patent	Died due to the laryngeal cancer at 2 months
Murray [34]	1971	1:0	-	0	-	-	-	-	Alive and symptom free at 10 months
Zintel [35]	1960	1:0	14	0	Right arm ischaemia, wound infection	-	-	-	Alive and no change in pre-operative neurological deficit at 36 months
Full median sternotomy with anterior neck dissection									
Ikonomidis [36]	2004	1:0	7	0	Persistent arm swelling	Patent	-	Patent	Alive and symptom free at 12 months
Takaba [37]	2003	1:0	20	-	-	-	-	-	-
Kasashima [38]	2000	1:0	34	0	Right hemianopia	-	-	-	Alive, right upper quadrantic hemianopia and right facial anhidrosis on day 34
Tominage [7]	1988	-	-	-	-	-	-	-	-
Schumacher [39]	1979	1:0	14	0	Respiratory dysfunction	-	-	-	Alive, right vocal paralysis and hoarseness persisted, dysphagia relieved at 9 months
Cook [40]	1960	1:0	-	1	-	-	-	-	-
		1:0	70	0	Infection	-	Paresis, haemorrhage, reintervention	-	-
Kirby [8]	1953	1:0	17	0	Paralysis of left arm	-	Paresis	-	-

Table 1 Summary of observed short and long-term complications (Continued)

Thoracotomy											
	Cook [40]	1960	1:0	-	0	-	-	-	-	-	Alive and symptom free at 55 months. Improvement of aneurysm
Conservative											
	Yang [41]	2009	1:0	-	-	-	-	-	-	-	-
	Butman [42]	1983	1:0	-	1	Brain stem/cerebellar infarct	-	-	-	-	-
Unspecified											
	Gordon-Taylor [43]	1950	-	-	19	Hemiplegia (2), cerebral symptoms (2), haemorrhage (4), uraemia (1), Respiratory dysfunction/failure (2), pneumonia (1), mediastinitis (1), infection (2), reintervention (1)	Obstructed=1	Paresis (1), cardiac breakdown (1), haemorrhage (2), persistent pulsation (1), rupture of aneurysm (1), ligature cut through aorta (1), pneumonia (1), nephritis (1), recurrence (2)	-	-	10 deaths

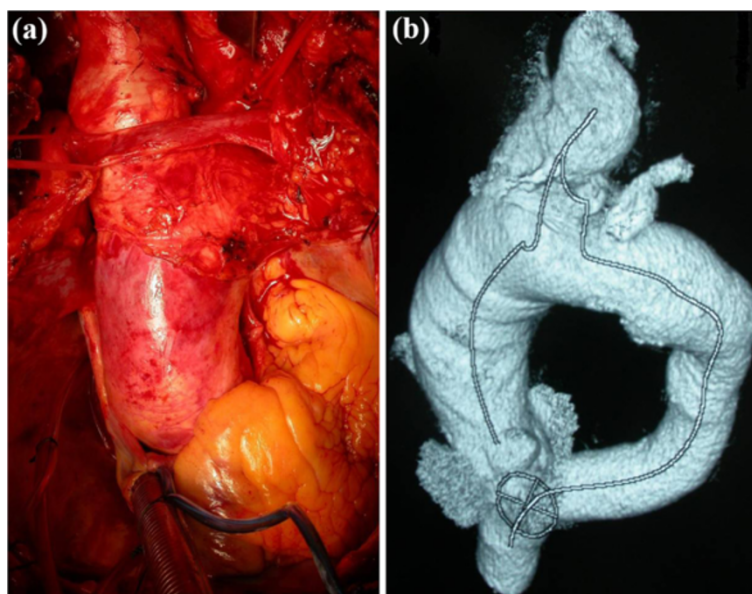


Figure 1 (a) Intra-operative finding of a large IA aneurysm extending into the aortic arch (b) Pre-operative 3D CT reconstruction of the aneurysmal segment.

tomographic angiogram visualized a degenerative aneurysm of the ascending aorta (5.5cm), proximal arch (4.2cm) and innominate artery (4.6cm) (Figure 1).

Under general anaesthesia, median sternotomy was performed extended into the right neck along the medial edge of the sternocleidomastoid. A second left subclavicular incision was made to expose the left axillary artery. Following systemic heparinization, cardiopulmonary bypass (CPB) was instituted with an arterial cannula introduced in the left axillary artery and a two-stage venous cannula introduced into the right atrium, maintaining a flow rate between 2.2 and 2.4 L.min⁻¹.m⁻² Upon cardiac fibrillation, the ascending aorta was cross-clamped and resected above the coronary ostia at the level of the sinotubular junction. Myocardial arrest was achieved using cold crystalloid cardioplegia (25 ml.kg⁻¹).

A four-limbed (28 × 10 × 8 × 8 × 10mm) Dacron aortic arch graft was prepared and anastomosed proximally to the aortic sinotubular junction with external Teflon strip reinforcement. At a target bladder temperature of 26°C, the patient was placed in the Trendelenburg position; CPB flow arrested, and the residual ascending aorta and proximal arch were resected preserving the ostia of the IA, left common carotid (LCCA) and left subclavian (LSA) arteries. The aneurysmatic IA was completely resected from its origin in the arch until its distal bifurcation to the right subclavian (RSA) and right common carotid (RCCA) arteries. Unilateral antegrade selective cerebral perfusion (ASCP = 10ml/kg/min, maintenance radial pressure 50mmHg) was instituted via a cerebral perfusion catheter to the LCCA and placing soft clamps to the RSA, RCCA and LSA. Cerebral monitoring was

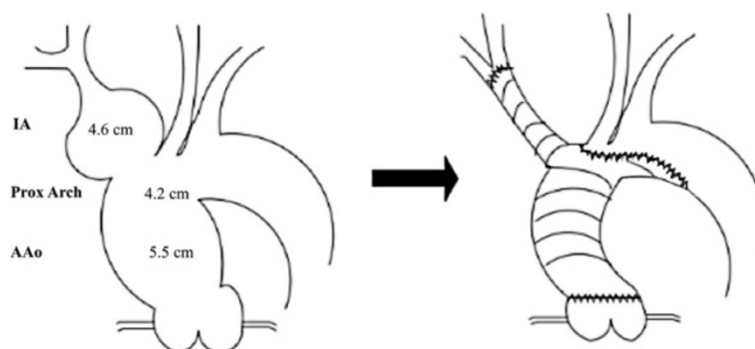


Figure 2 Schematic demonstrating pre-operative anatomy and surgical repair.

achieved by means of transcutaneous cerebral oximetry and electroencephalogram.

The Dacron graft was trimmed and the two distal side limbs (8mm) ligated. The distal end was anastomosed in a hemiarch fashion to the aortic arch proximal to the origin of LCCA and reinforced with external Teflon strips. The side branch of the graft was then anastomosed in an end-to-end fashion to the distal IA. After systematic de-airing, the distal anastomosis to the arch was completed, and systemic perfusion and rewarming commenced (Figures 2 and 3).

The CPB time was 110 minutes, ASCP time 45 minutes, lower body circulatory arrest time 38 minutes and myocardial ischemic time 85 minutes. The patient was extubated 12 hours after surgery with a total ITU stay of 2 days. The post-operative course was unremarkable. Repeat CT three months after surgery and showed an excellent result.

Conclusions

Since its first description by Valentine Mott in 1818, significant advances have been made in the surgical repair of innominate artery aneurysms. Most attempts in 19th and the beginning of 20th century were limited to ligation of the aneurysm, resulting in mortality rates as high as 30–78% [5]. Although the method described by Kimura in 1908 involving triple ligation and excision of the aneurysm was technically successful [35], cerebral injury following the ligation of the right common carotid was a serious complication. It was not until 1952, when Kirby and Johnson [38] had reported successful resection of IA aneurysm and reconstruction of circulation to RCCA by end-to-end anastomosis. Utilization of bifur-

cated aortic homograft by DeBakey and Crawford in 1956 [42] and introduction of the bifurcated Dacron graft by Hejhal et al. [43] in 1965 were milestones in reducing the mortality to recently observed levels of 5% [3]. However, operative mortality rate of emergency operations are still being reported as 50% [3], emphasising the need for early elective repair where possible.

Today the commonest surgical approaches to the IA include median hemisternotomy combined with right anterior thoracotomy in the 3rd intercostal space and the right supraclavicular fossa, median sternotomy with extension along the medial border the right sternocleidomastoid muscle and the more recently reported cervical approach (Table 1).

Although employed less frequently than open surgical repair, endovascular, minimal access cervical or hemisternotomy techniques have more recently been associated with fewer short-term complications, shorter hospital stay, comparable graft patency and similar short- and long-term mortality to open surgery (Table 1). However despite these potential benefits, careful patient selection is needed and long-term outcome data remains lacking. Endovascular treatments can also be challenging in cases of bovine arch morphology [16], where the aneurysmal neck is inadequate for attachment of the graft or when the distal innominate artery is involved [7,11]. Furthermore, covered endovascular stents may require long-term antiplatelet therapy and a closed approach presents diagnostic difficulty in ruling out any malignant processes underlying aneurysm formation [18].

This case demonstrates the safe application of median sternotomy with extension to the right anterior neck to perform open repair of a large, complex aneurysm of the

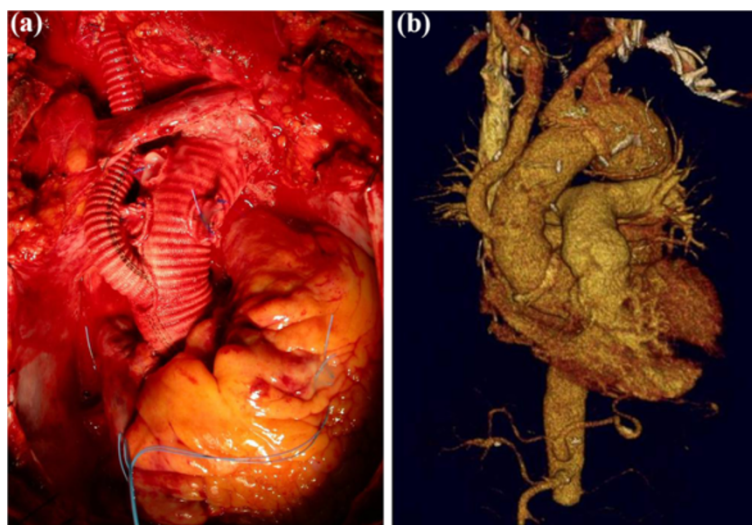


Figure 3 Post operative images demonstrating (a) Final open surgical repair (b) 3D CT reconstruction demonstrating in situ graft reconstruction.

IA involving the aortic arch. Although open repair carries a relatively higher short-term post-operative morbidity (Table 1), improvement in surgical techniques over the course of the last century has facilitated excellent long-term results. However, the increasing use of minimally invasive strategies presents an emerging alternative in the surgical treatment of these patients. The heterogeneous nature of multiple small studies with a lack of large multi-centre studies and late follow up however limits the data currently available. Further research is therefore required to assess both the long-term patency and mortality associated with minimally invasive surgical approaches.

Consent

Written informed consent was obtained from the patient for publication of this Case report and any accompanying images. A copy of the written consent is available for review by the Editor-in-Chief of this journal.

Abbreviations

IA: Innominate artery; CPB: Cardiopulmonary bypass; LCCA: Left common carotid artery; LSA: Left subclavian artery; RSA: Right subclavian artery; RCCA: Right common carotid artery; ASCP: Antegrade selective cerebral perfusion.

Competing interests

There are no financial or non-financial competing interests.

Authors' contributions

JK, VA, DT and CC carried out the surgical procedure, participated in provision of clinical information and reviewed the manuscript. ES and LH performed the literature review and drafted the manuscript with supervision and assistance from HA and TA. LH, HA and TA finalized the manuscript. All authors read and approved the final manuscript.

Author details

¹Department of Surgery and Cancer, Imperial College London, London, UK.

²Second Department of Cardiac Surgery, Evangelismos General Hospital

Athens, Athens, Greece. ³Department of Surgery and Cancer, Imperial College London, 10th floor QEOM Building, St. Mary's Hospital, Praed Street, London W2 1NY, UK.

Received: 29 April 2013 Accepted: 31 May 2013

Published: 1 June 2013

References

- Stolf NA, Bittencourt D, Verginelli G, Zerbini EJ: Surgical treatment of ruptured aneurysms of the innominate artery. *Ann Thorac Surg* 1983, **35**(4):394-399.
- Cury M, Greenberg RK, Morales JP, Mohabbat W, Hernandez AV: Supra-aortic vessels aneurysms: diagnosis and prompt intervention. *J Vasc Surg* 2009, **49**(1):4-10.
- Bower TC, Pairolero PC, Hallett JW Jr, Toomey BJ, Glociczki P, Cherry KJ Jr: Brachiocephalic aneurysm: the case for early recognition and repair. *Ann Vasc Surg* 1991, **5**(2):125-132.
- Cherry K: Treatment of extracranial, carotid, innominate, subclavian and axillary aneurysms. In *Mastery of vascular and endovascular surgery: An illustrated review*. Edited by Zelenock GB, Huber TS, Messina LM, Lumsden AB, Moneta GL. Philadelphia, Pa: Lippincott, Williams & Wilkins; 2006:79-84.
- Kieffer E, Chiche L, Koskas F, Bahnnini A: Aneurysms of the innominate artery: surgical treatment of 27 patients. *J Vasc Surg* 2001, **34**(2):222-228.
- Kraus TW, Paetz B, Richter GM, Allenberg JR: The isolated posttraumatic aneurysm of the brachiocephalic artery after blunt thoracic contusion. *Ann Vasc Surg* 1993, **7**(3):275-281.
- Angiletta D, Marinazzo D, Guido G, Fullone M, Pulli R, Regina G: Eight-year follow-up of endovascular repair of a brachiocephalic trunk aneurysm due to Takayasu's arteritis. *J Vasc Surg* 2012, **56**(2):504-507.
- Taha MM, Nakahara I, Higashi T, Iwamuro Y, Watanabe Y, Taki W: Interventional neuroradiological techniques for the treatment of aneurysms of the supra-aortic extracranial arteries. *Neurol Med Chir* 2010, **50**(4):275-280.
- Puech-Leão P, Orra HA: Endovascular repair of an innominate artery true aneurysm. *J Endovasc Ther* 2001, **8**(4):429-432.
- Park JH, Chung JW, Joh JH, Song SY, Shin SJ: Aortic and arterial aneurysms in behçet disease: management with stent-grafts- initial experience. *Radiology* 2001, **220**:745-750.
- Melissano G, Civilini E, Marrocco-Trischitta MM, Chiesa R: Hybrid endovascular and off-pump open surgical treatment for synchronous aneurysms of the aortic arch, brachiocephalic trunk, and abdominal aorta. *Tex Hear Inst J* 2004, **31**(3):283-287.
- Takach TJ, Lalka SG: Innominate artery aneurysm: axial reconstruction via a cervical approach. *J Vasc Surg* 2007, **46**(6):1267-1269.
- MacLean AA, Vricella LA, Freischlag JA: Innominate artery aneurysm. *Eur J Cardiothorac Surg* 2007, **32**(5):803.
- Mori K, Kasuga C, Nakao Y, Yamamoto T, Maeda M: Intracranial pseudoaneurysm due to rupture of a saccular aneurysm mimicking a large partially thrombosed aneurysm ("ghost aneurysm"): radiological findings and therapeutic implications in two cases. *Neurosurg Rev* 2004, **27**(4):289-293.
- Lane JD, Peirce EC: Endoaneurysmorrhaphy for spontaneous innominate artery aneurysm; report of a case with cure and an important diagnostic complication. *Surgery* 1951, **30**(4):709-717.
- Constenla I, Alvarez B, Yugueros X, Fernandez E, Bofill R, Matas M: Innominate artery aneurysm with hemoptysis and airway compression in a patient with bovine aortic arch. *J Vasc Surg* 2012, **56**(3):822-825.
- Oswal A, Mehra A, Karbhase J, Johari A, Karatela R, Shivdasani B: Combined resection of coronary and innominate artery aneurysms. *J Card Surg* 2011, **26**(3):319-321.
- Lu C-Y, Lu M-S, Huang Y-K, Tsai F-C, Lin PJ: Innominate artery aneurysm as presentation of angiosarcoma. *Surgery* 2011, **149**(4):593-594.
- Yuan S-M, Tager S: Penetrating atherosclerotic ulcer aneurysm of the innominate artery. *VASA Zeitschrift für Gefässkrankheiten* 2009, **38**(3):263-266.
- Da Col U, Koukoulis G, Di Bella I, Ramoni E, Ragni T: Surgical treatment of ascending aorta and innominate artery trunk aneurysm with displaced brachiocephalic vessels. *J Cardiovasc Med (Hagerstown)* 2007, **8**(10):852-854.
- Oruganti SS, Mishra RC: Traumatic giant true aneurysm of the brachiocephalic artery. *Asian Cardiovasc Thorac Ann* 2006, **14**(4):352-353.
- Saito A, Shiono M, Yamamoto T, Inoue T, Hata M, Sezai A, Iida M, Niino T, Hattori T, Negishi N, Sezai Y: Surgical treatment for innominate artery aneurysm with a coronary pulmonary artery fistula: a case report. *Ann Thorac Cardiovasc Surg* 2005, **11**(1):55-58.
- Chiappini B, Arpesella G, Barbara C, Pierangeli A: Delayed post-traumatic aneurysms of aorta, carotid and innominate arteries. *European journal of cardio-thoracic surgery* 2001, **20**(6):1246-1248.
- Guibaud JP, Laborde MN, Dubrez J, Elia N, Remes J, Rosato F, Roques X, Baudet E: Surgical repair of an aneurysm of the innominate artery with fistulization into the trachea. *Ann Vasc Surg* 2001, **15**(3):412-414.
- Najafi H, Overman D, Kavinsky CJ: An unusual combination of cardiovascular surgical disorders. *Ann Thorac Surg* 1999, **67**(1):241-244.
- Villegas-Cabello O, Cooley DA: Aneurysm of the innominate artery with aberrant origin of the left carotid artery. Case report. *Tex Hear Inst J* 1996, **23**(4):298-300.
- Adkins MS, Gaines WE, Laub GW, Anderson WA, Fernandez J, McGrath LB: Management of an innominate artery aneurysm during an open heart operation. *Ann Thorac Surg* 1993, **56**(2):377-379.
- Thomas TV: Intrathoracic aneurysms of the innominate and subclavian arteries. *J Thorac Cardiovasc Surg* 1972, **63**(3):461-471.
- Ketonen P, Meurala H, Harjola PT, Mattila S, Ketonen L: Management of arteriosclerotic aneurysms of the innominate and subclavian arteries. *Scand J Thorac Cardiovasc Surg* 1983, **17**(2):129-133.
- Murray GF, Brawley RK, Gott VL: Reconstruction of the innominate artery by means of a temporary heparin-coated shunt bypass. *J Thorac Cardiovasc Surg* 1971, **62**(1):34-41.
- Zintel HA, Risbeck EC: Aneurysm of the bifurcation of the innominate artery. Successful excision and restoration of the carotid artery. *Am J Surg* 1960, **99**:929-933.

32. Ikonomidis JS, Kim PY, Crawford FA: **Repair of aortic arch coarctation and innominate artery aneurysm with branched Dacron graft.** *J Thorac Cardiovasc Surg* 2004, **127**(2):579–581.
33. Takaba K, Aota M, Koike H, Konishi Y: **Surgical treatment for intrathoracic aneurysm of the innominate artery in an 83-year-old asymptomatic woman.** *Jpn J Thorac Cardiovasc Surg* 2004, **52**(4):194–197.
34. Kasashima F, Urayama H, Ohtake H, Watanabe Y: **Intrathoracic aneurysm of the innominate and right subclavian arteries: report of a case.** *Surg Today* 2001, **31**(1):51–54.
35. Tominaga R, Tanaka J, Kawachi Y, Yoshitoshi M, Kohno H, Shiki K, Tokunaga K, Takahashi S: **Surgical treatment of respiratory insufficiency due to tracheobronchial compression by aneurysms of the ascending aorta and innominate artery.** *J Cardiovasc Surg* 1988, **29**(4):413–417.
36. Schumacher PD, Wright CB: **Management of of arteriosclerotic aneurysm of the innominate artery.** *Surgery* 1979, **85**(5):489–495.
37. Cook J: **A report on three cases of innominate aneurysm.** *J R Coll Surg Edinb* 1960, **5**:298–303.
38. Kirby CK, Johnson J: **Innominate artery aneurysm treated by resection and end-to-end anastomosis.** *Surgery* 1953, **33**(4):562–566.
39. Yang G, Thompson D, Warren A: **Late-appearing brachiocephalic aneurysm: an atypical vascular sequella of Kawasaki disease.** *Pediatr Cardiol* 2009, **30**(2):197–199.
40. Butman S, Gardin JM, Knoll M: **Innominate artery aneurysm with thrombus: detection by two-dimensional echocardiography.** *J Am Coll Cardiol* 1983, **2**(2):387–390.
41. Gordon-Taylor G: **The surgery of the innominate artery, with special reference to aneurysm.** *Br J Surg* 1950, **37**(148):377–404.
42. De Bakey ME, Crawford ES: **Resection and homograft replacement of innominate and carotid arteries with use of shunt to maintain circulation.** *Surg Gynecol Obstet* 1957, **105**(2):129–135.
43. Hejhal L, Firt P, Michal V, Hejhal J: **Some interesting case reports in the field of reconstructive vascular surgery.** *J Cardiovasc Surg* 1965, **6**(5):409–415.

doi:10.1186/1749-8090-8-141

Cite this article as: Soyly *et al.*: Surgical treatment of innominate artery and aortic aneurysm: a case report and review of the literature. *Journal of Cardiothoracic Surgery* 2013 **8**:141.

Submit your next manuscript to BioMed Central and take full advantage of:

- **Convenient online submission**
- **Thorough peer review**
- **No space constraints or color figure charges**
- **Immediate publication on acceptance**
- **Inclusion in PubMed, CAS, Scopus and Google Scholar**
- **Research which is freely available for redistribution**

Submit your manuscript at
www.biomedcentral.com/submit

